

Central Nervous System

“CNS”

Mr. Ravikumar R. Thakar

Assistant Professor

Department of Pharmacology & Pharmacy Practice

Saraswati Institute of Pharmaceutical Sciences

At. & Po. Dhanap, Ta. & Dist.: Gandhinagar, Gujarat, India - 382355

The Spinal Cord

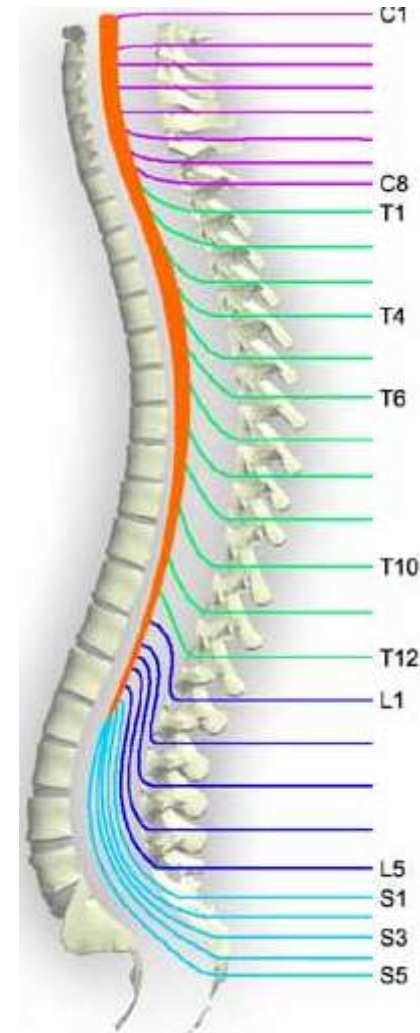
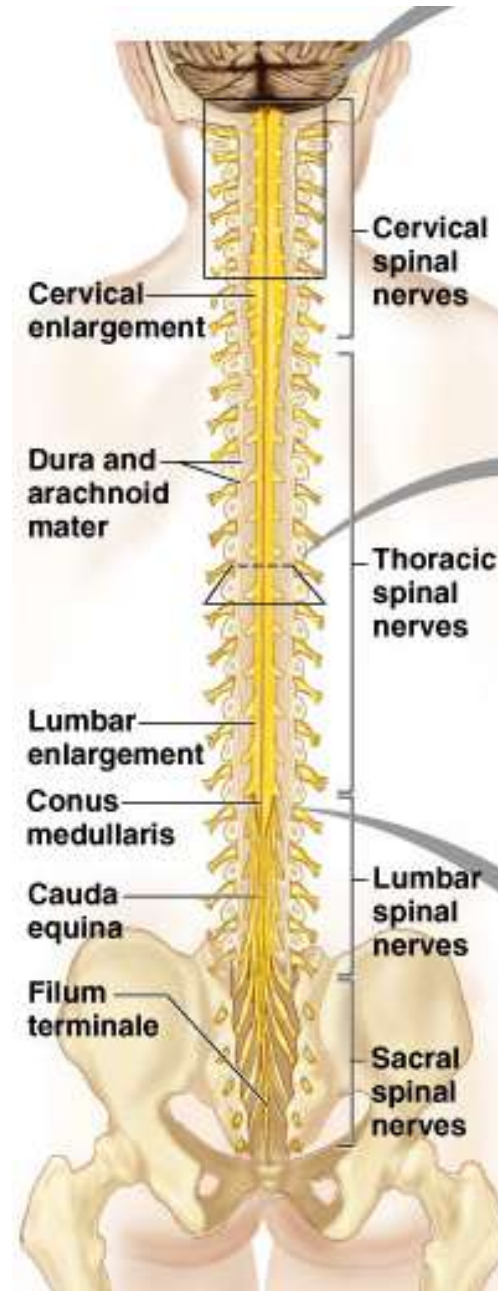
- Foramen magnum to L1 or L2
- Runs through the vertebral canal of the vertebral column

- Functions
 1. ***Sensory and motor innervation*** of entire body inferior to the head through the ***spinal nerves***
 2. ***Two-way conduction pathway*** between the body and the brain
 3. ***Major center for reflexes***

THANKING YOU

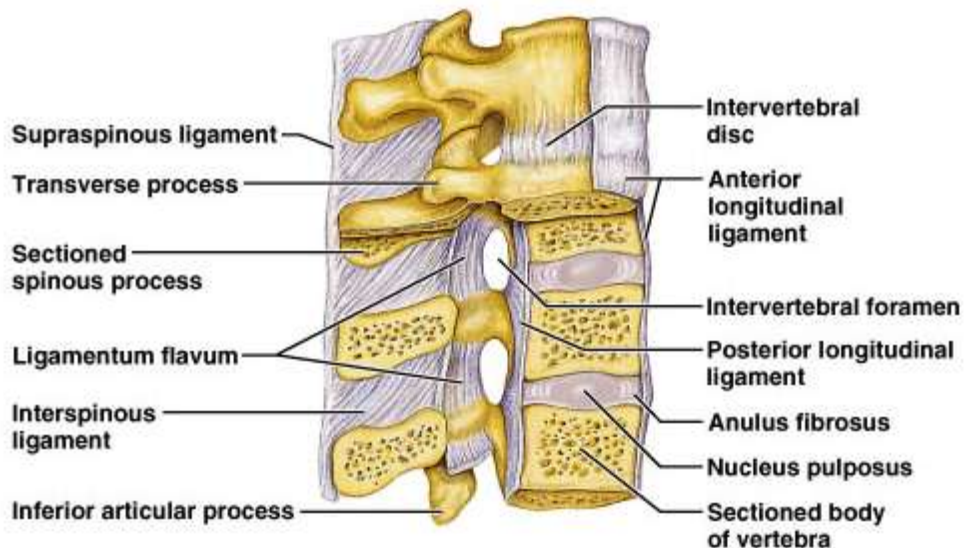
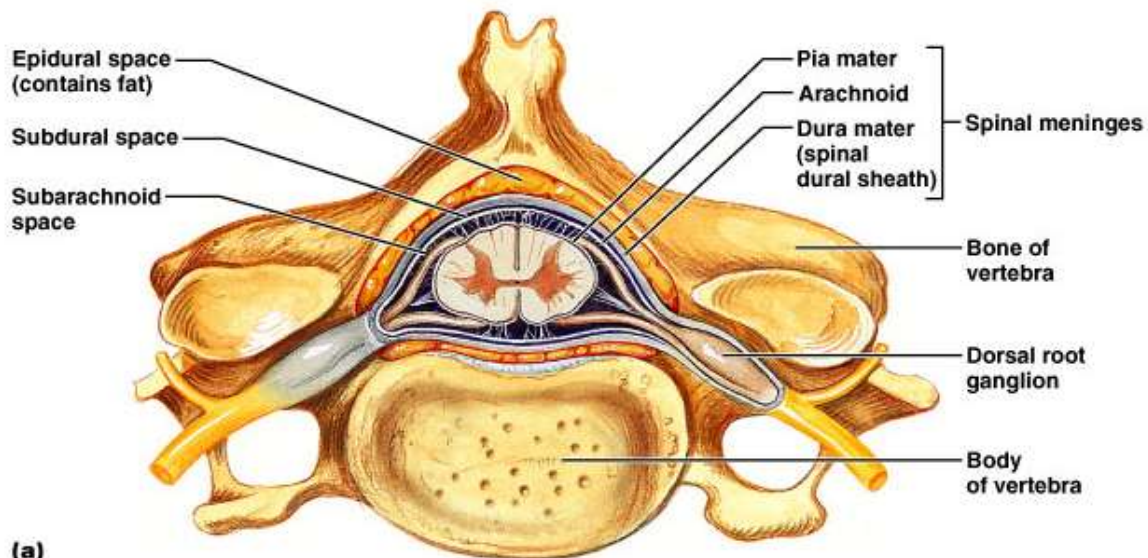
Spinal cord

- Fetal 3rd month: ends at coccyx
- Birth: ends at L3
- Adult position at approx L1-2 during childhood
- End: *conus medullaris*
 - This tapers into *filum terminale* of connective tissue, tethered to coccyx
- Spinal cord segments are superior to where their corresponding spinal nerves emerge through intervertebral foramina (see also fig 17.5, p 288)
- *Denticulate ligaments*: lateral shelves of pia mater anchoring to dura (meninges: more later)



Spinal nerves

- Part of the peripheral nervous system
- 31 pairs attach through dorsal and ventral nerve roots
- Lie in intervertebral foramina

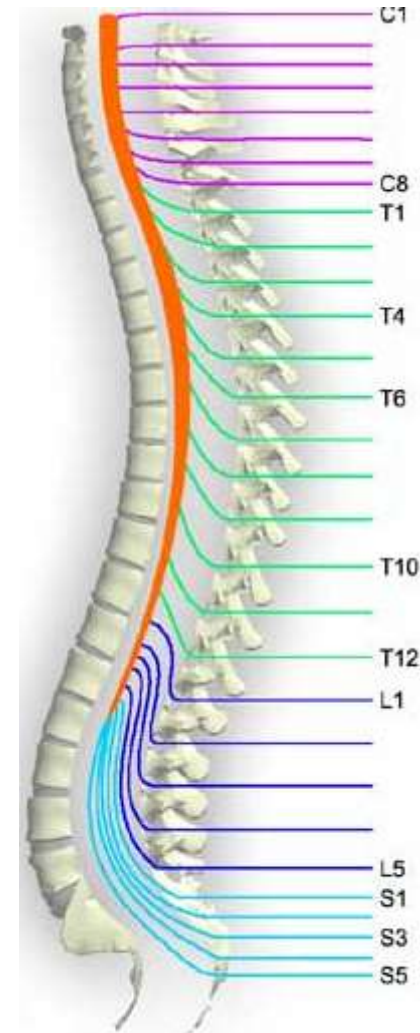


Spinal nerves continued

- Divided based on vertebral locations
- 8 cervical
- 12 thoracic
- 5 lumbar
- 5 sacral
- 1 coccygeal
- *Cauda equina* (“horse’s tail”): collection of nerve roots at inferior end of vertebral canal

Spinal nerves continued

- Note: cervical spinal nerves exit from *above* the respective vertebra
 - Spinal nerve root 1 from above C1
 - Spinal nerve root 2 from between C1 and C2, etc.
- Clinically, for example when referring to disc impingement, both levels of vertebra mentioned, e.g. C6-7 disc impinging on root 7
- Symptoms usually indicate which level



More about spinal nerves in the peripheral nervous system lecture

Protection:

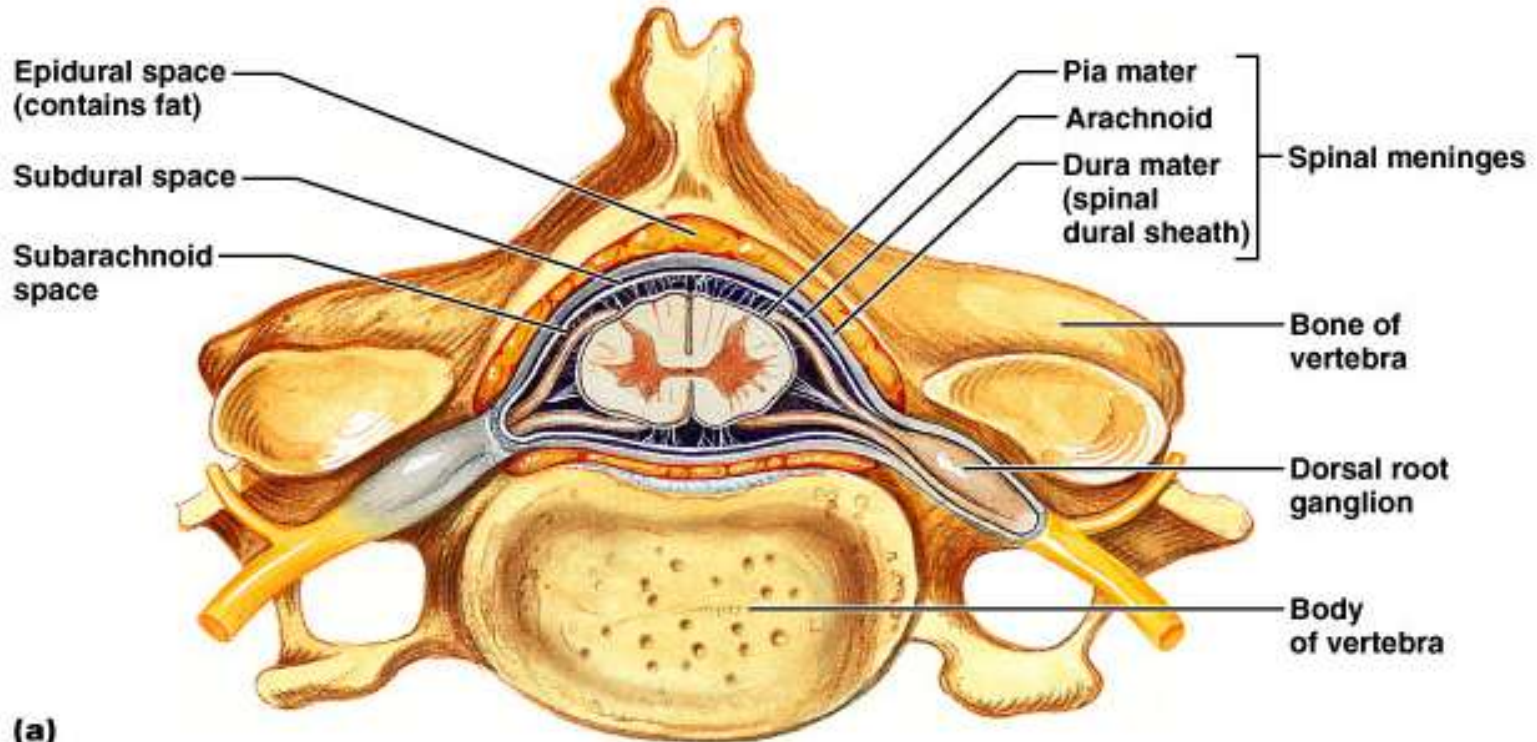
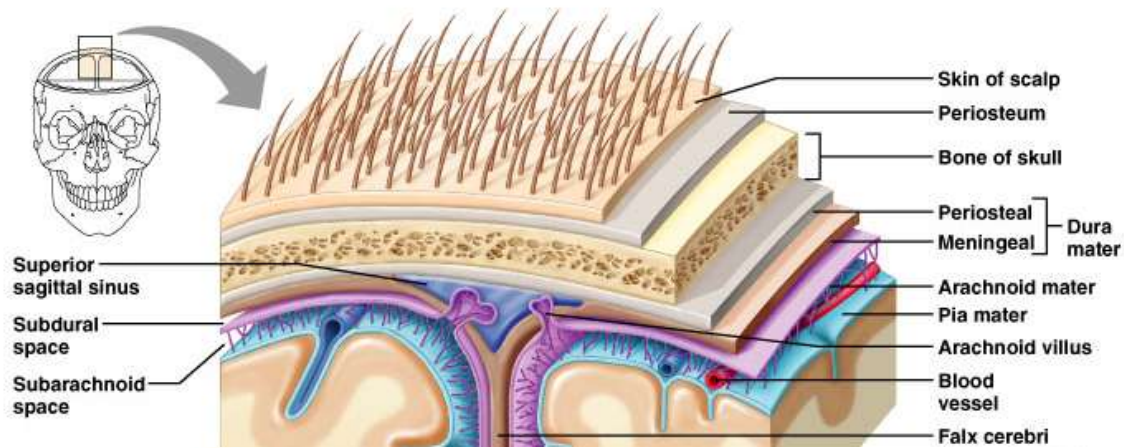
Bone
Meninges
CSF (cerebrospinal fluid)

3 meninges:

- dura mater (outer)
- arachnoid mater (middle)
- pia mater (inner)

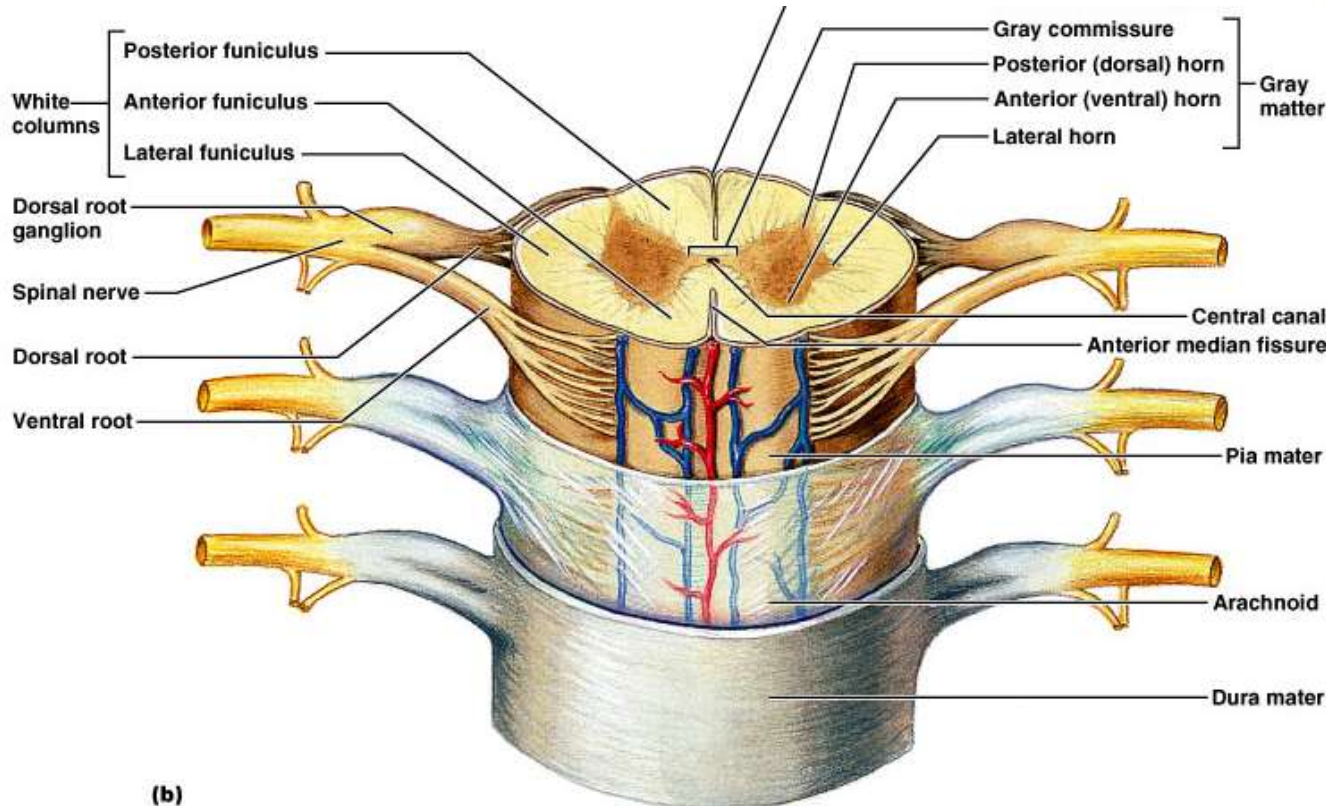
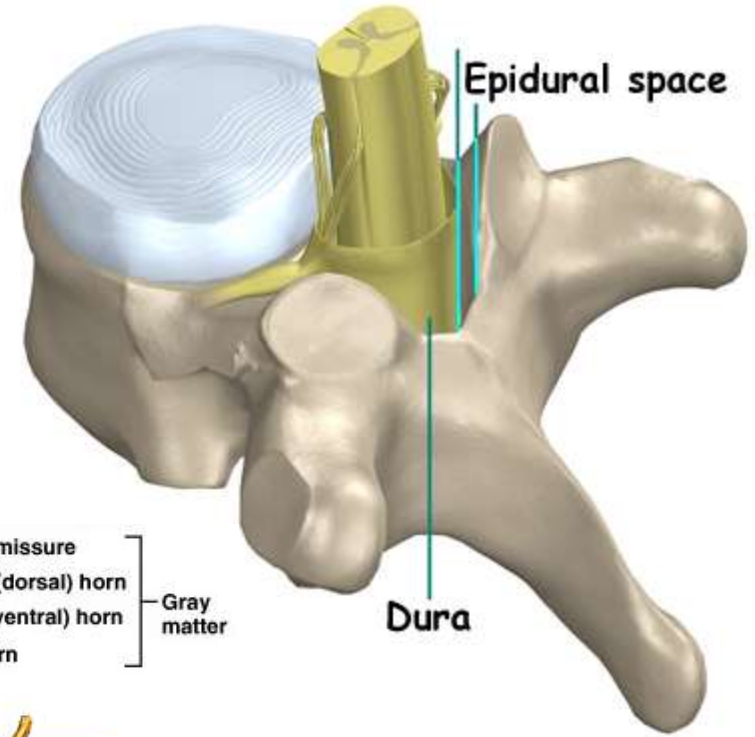
3 potential spaces

- epidural: outside dura
- subdural: between dura & arachnoid
- subarachnoid: deep to arachnoid



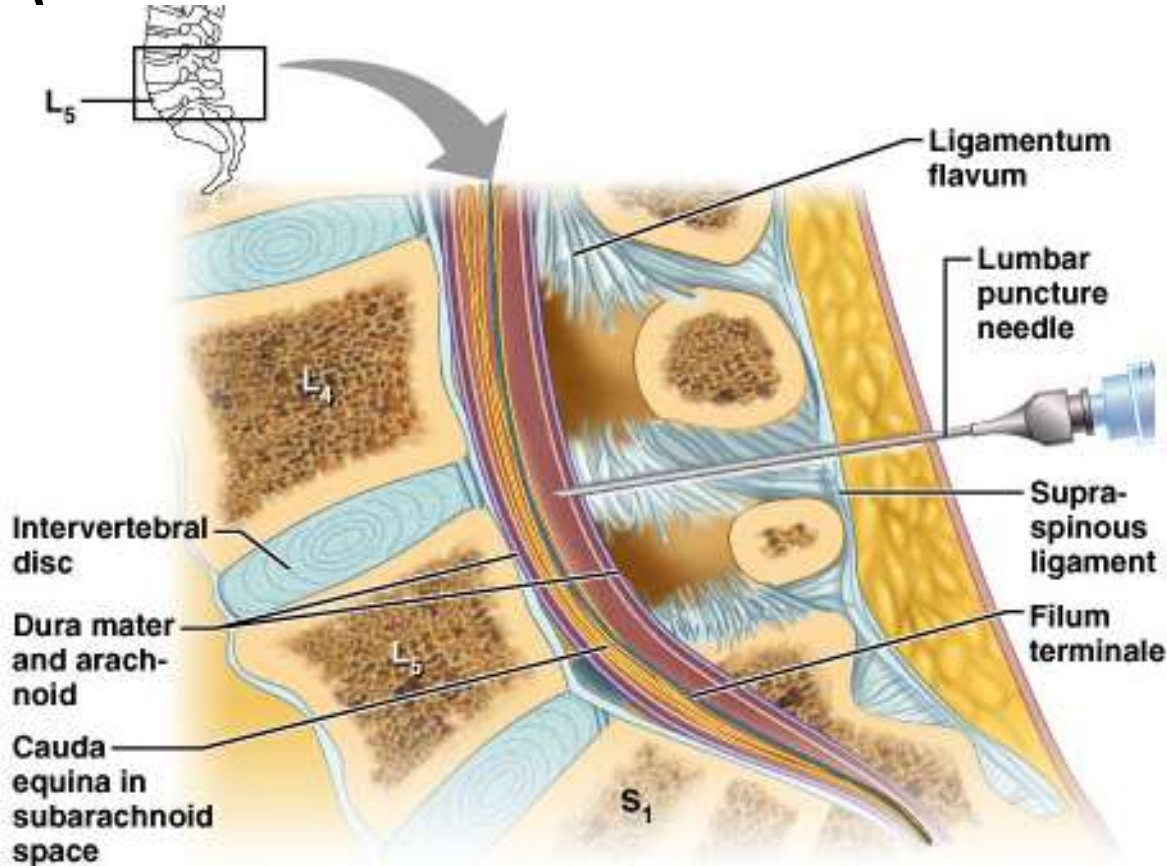
Spinal cord coverings and spaces

http://www.eorthopod.com/images/ContentImages/pm/pm_general_esi/pmp_general_esi_epidural_space.jpg



LP (lumbar puncture) = spinal tap

(needle introduced into **subdural** space to collect CSF)



Lumbar spine
needs to be flexed
so can go between
spinous processes

Originally thought to be a narrow fluid-filled interval between the dural and arachnoid; now known to be an artificial space created by the separation of the arachnoid from the dura as the result of trauma or some ongoing pathologic process; in the healthy state, the arachnoid is attached to the dura and a naturally occurring subdural space is not present.
<http://cancerweb.ncl.ac.uk/cgi-bin/omd?subdural+space>

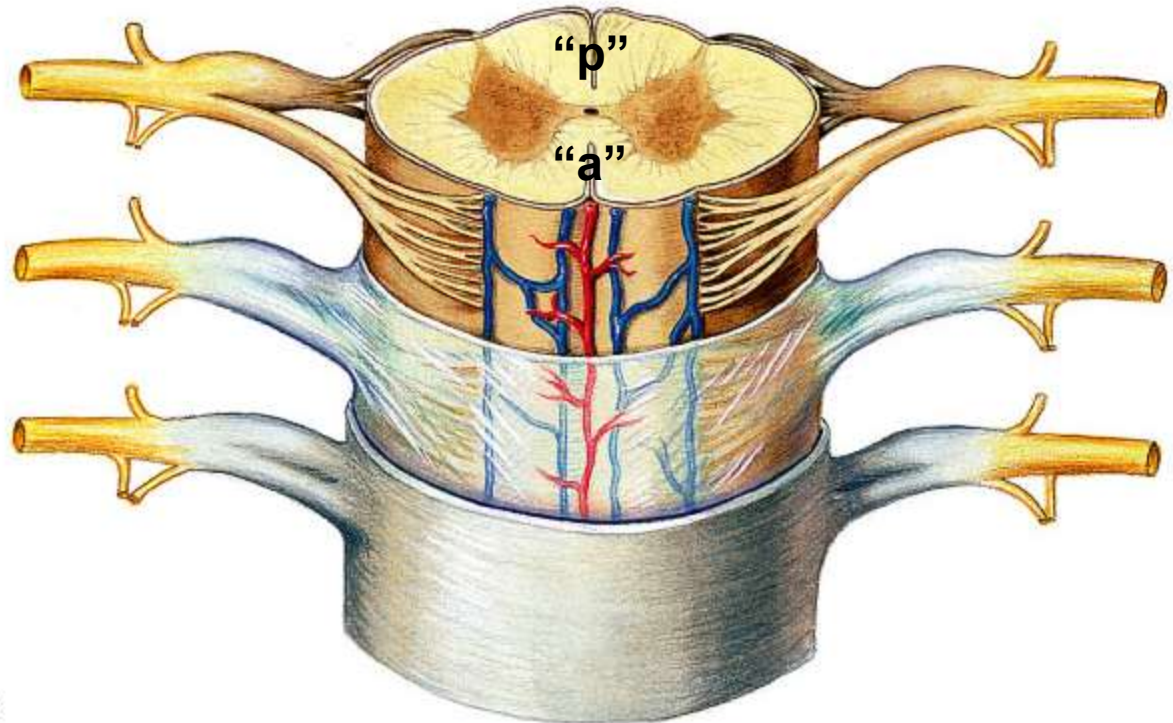
Epidural space is **external** to dura

Anesthetics are often injected into epidural space

Injection into correct space is vital; mistakes can be lethal

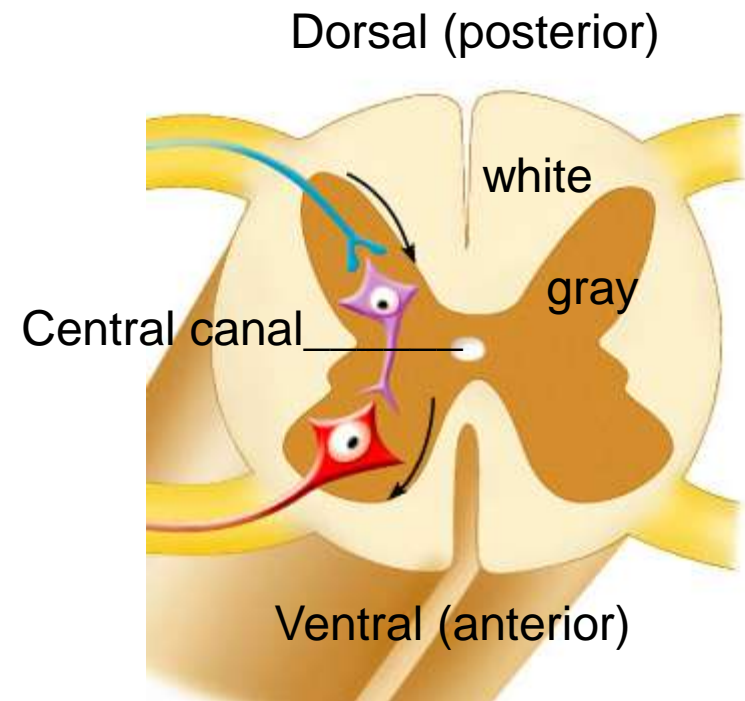
Spinal cord anatomy

- Posterior median sulcus (“p”)
- Anterior median fissure (“a”)
- White matter (yellow here)
- Gray matter (brown here)



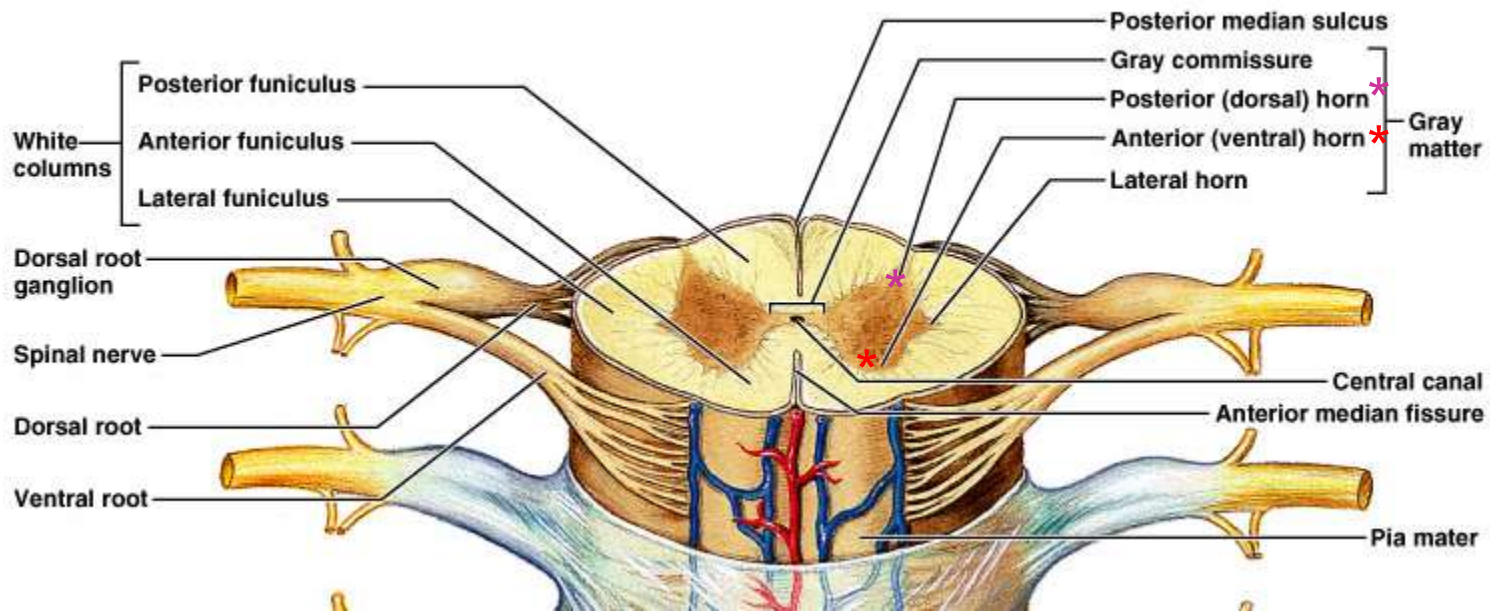
Gray/White in spinal cord

- Hollow central cavity (“central canal”)
- Gray matter surrounds cavity
- White matter surrounds gray matter (white: ascending and descending tracts of axons)
- “H” shaped on cross section
- Dorsal half of “H”: **cell bodies of interneurons**
- Ventral half of “H”: **cell bodies of motor neurons**
- No cortex (as in brain)



Spinal cord anatomy

- Gray commissure with central canal
- Columns of gray running the length of the spinal cord
 - Posterior (dorsal) horns (*cell bodies of interneurons*)
 - Anterior (ventral) horns (*cell bodies of motor neurons*)
- Lateral horns in thoracic and superior lumbar cord



White matter of the spinal cord

(myelinated and unmyelinated axons)


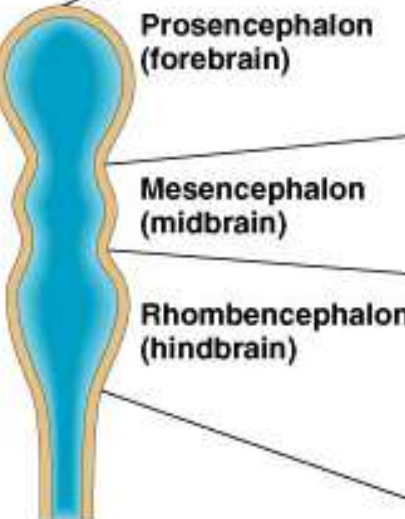




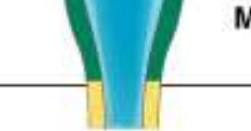

- **Ascending** fibers: sensory information from sensory neurons of body up to brain
- **Descending** fibers: motor instructions from brain to spinal cord
 - Stimulates contraction of body's muscles
 - Stimulates secretion from body's glands
- **Commissural** fibers: white-matter fibers crossing from one side of cord to the other
- Most pathways cross (or **decussate**) at some point
- Most synapse two or three times along the way, e.g. in brain stem, thalamus or other

The Brain: embryonic development

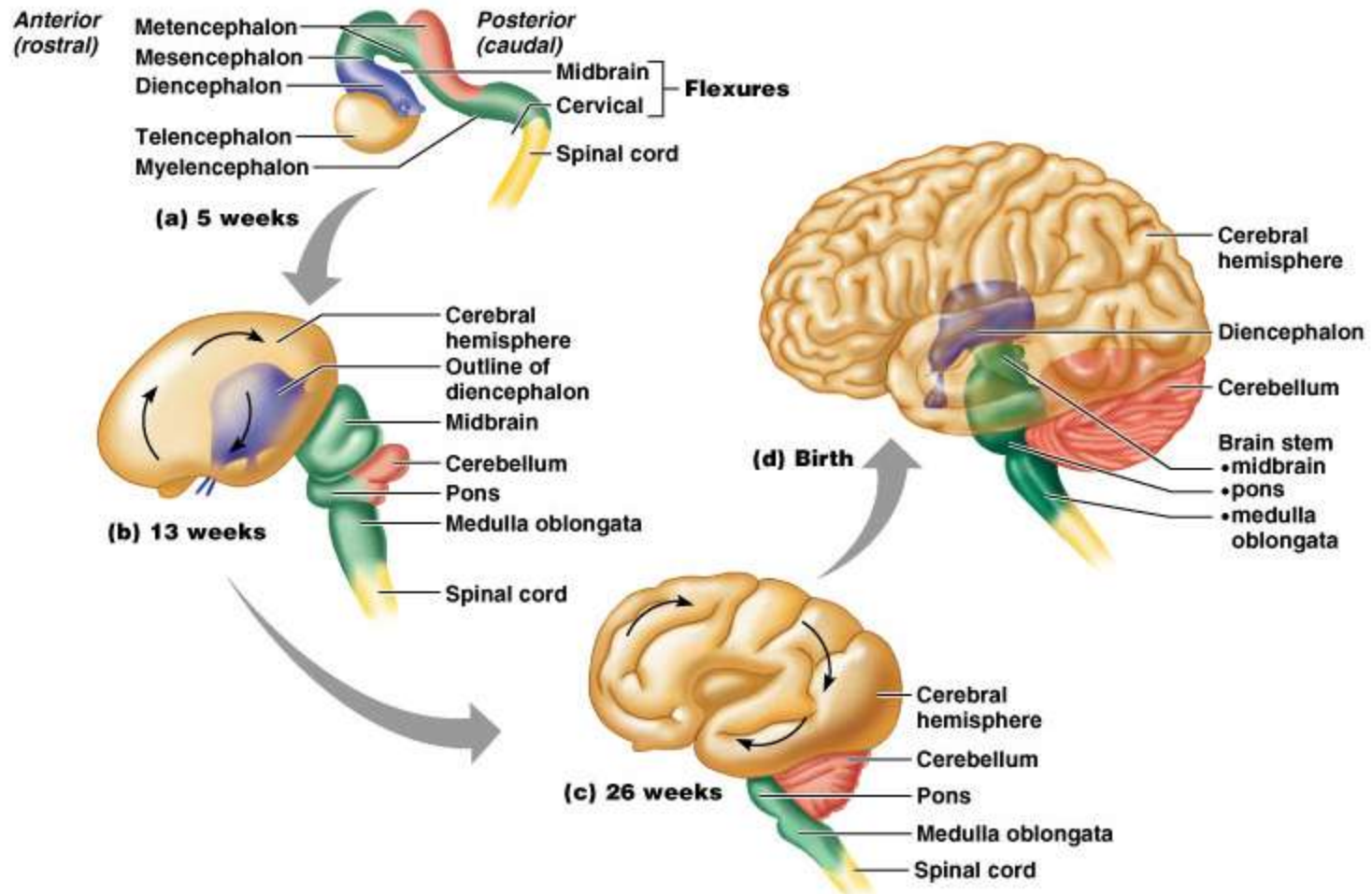
- Develops from neural tube
- Brain subdivides into
 - Forebrain
 - Midbrain
 - Hindbrain
- These further divide, each with a fluid filled region: ventricle, aqueduct or canal
 - Spinal cord also has a canal
- Two major bends, or flexures, occur (midbrain and cervical)

Brain development

- Learn forebrain, midbrain and hindbrain in (b)
- See next color coded pics in reference to (d)
- Learn (e)
- *Encephalos* means brain (otherwise you don't need to learn "c")

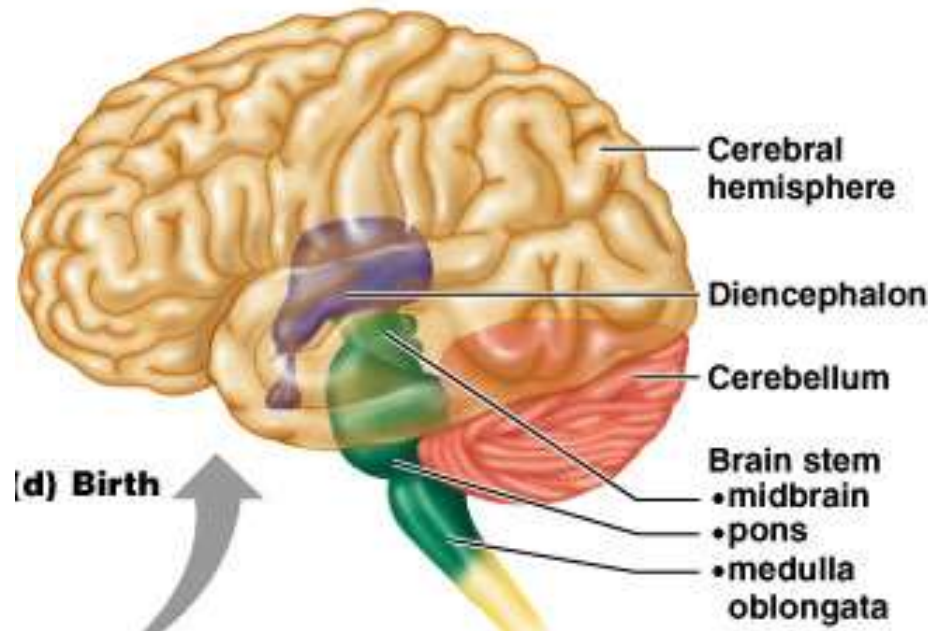
(a) Neural tube	(b) Primary brain vesicles	(c) Secondary brain vesicles	(d) Adult brain structures	(e) Adult neural canal regions
 <p>Anterior (rostral)</p> <p>Posterior (caudal)</p>	 <p>Prosencephalon (forebrain)</p> <p>Mesencephalon (midbrain)</p> <p>Rhombencephalon (hindbrain)</p>	 <p>Telencephalon</p>	<p>Cerebrum: Cerebral hemispheres (cortex, white matter, basal nuclei)</p>	<p>Lateral ventricles</p>
		 <p>Diencephalon</p>	<p>Diencephalon (thalamus, hypothalamus, epithalamus)</p>	<p>Third ventricle</p>
		 <p>Mesencephalon</p>	<p>Brain stem: midbrain</p>	<p>Cerebral aqueduct</p>
		 <p>Metencephalon</p>	<p>Brain stem: pons</p>	<p>Fourth ventricle</p>
		 <p>Myelencephalon</p>	<p>Cerebellum</p> <p>Brain stem: medulla oblongata</p>	
		 <p>Myelencephalon</p>	<p>Spinal cord</p>	<p>Central canal</p>

- Space restrictions force cerebral hemispheres to grow posteriorly over rest of brain, enveloping it
- Cerebral hemispheres grow into horseshoe shape (b and c)
- Continued growth causes creases, folds and wrinkles



Anatomical classification

- Cerebral hemispheres
- Diencephalon
 - Thalamus
 - Hypothalamus
- Brain stem
 - Midbrain
 - Pons
 - Medulla
- Cerebellum
- Spinal cord



(d) Adult brain structures
Cerebrum: Cerebral hemispheres (cortex, white matter, basal nuclei)
Diencephalon (thalamus, hypothalamus, epithalamus)
Brain stem: midbrain
Brain stem: pons
Cerebellum
Brain stem: medulla oblongata
Spinal cord

(d) Adult brain structures

Cerebrum: Cerebral hemispheres (cortex, white matter, basal nuclei)

Diencephalon (thalamus, hypothalamus, epithalamus)

Brain stem: midbrain

Brain stem: pons

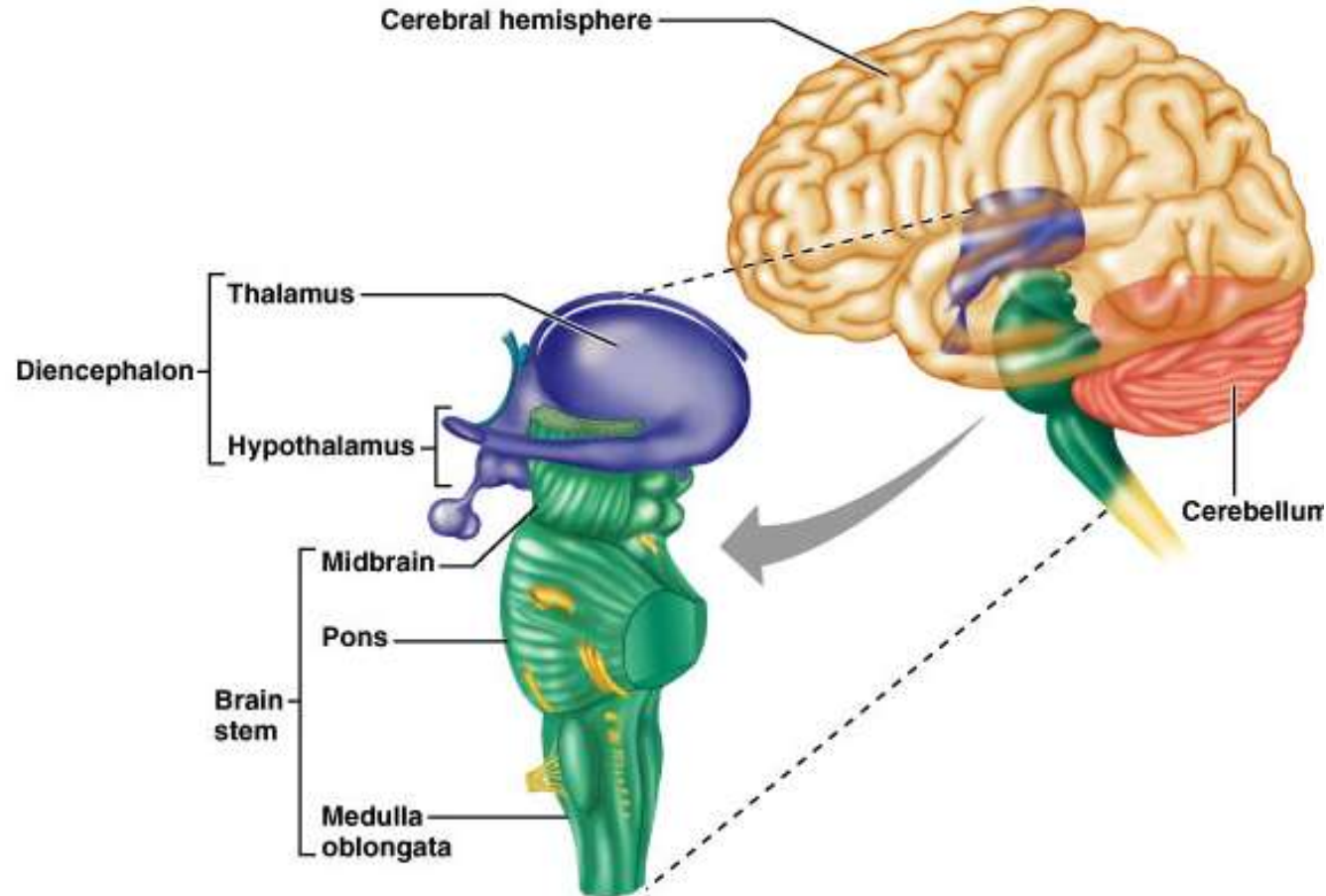
Cerebellum

Brain stem: medulla oblongata

Spinal cord

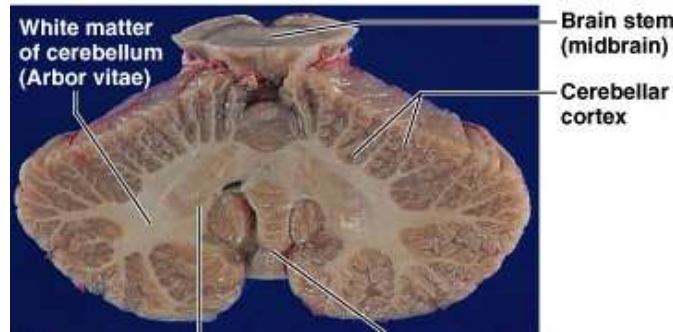
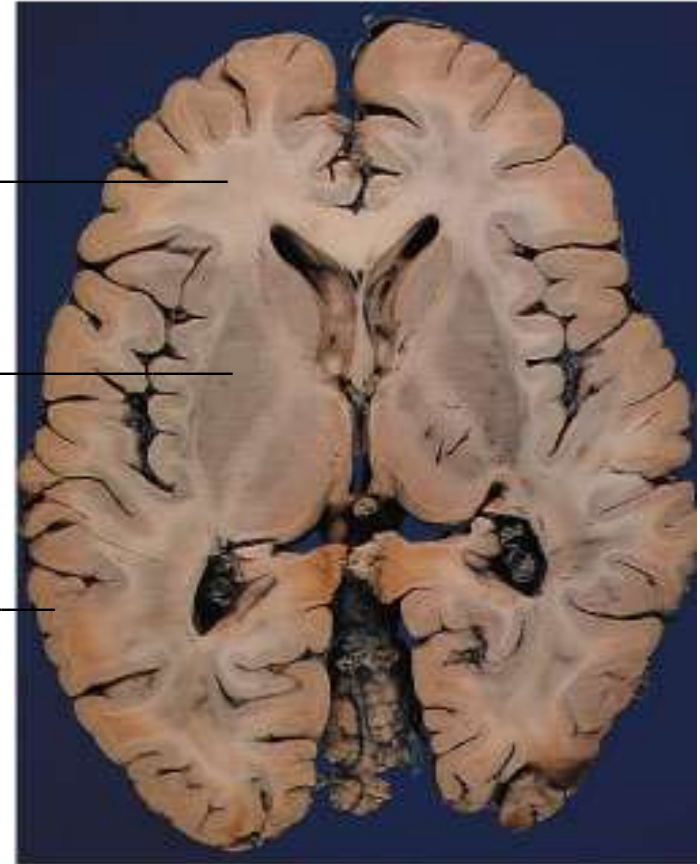
Parts of Brain

Cerebrum
Diencephalon
Brainstem
Cerebellum



Usual pattern of gray/white in CNS

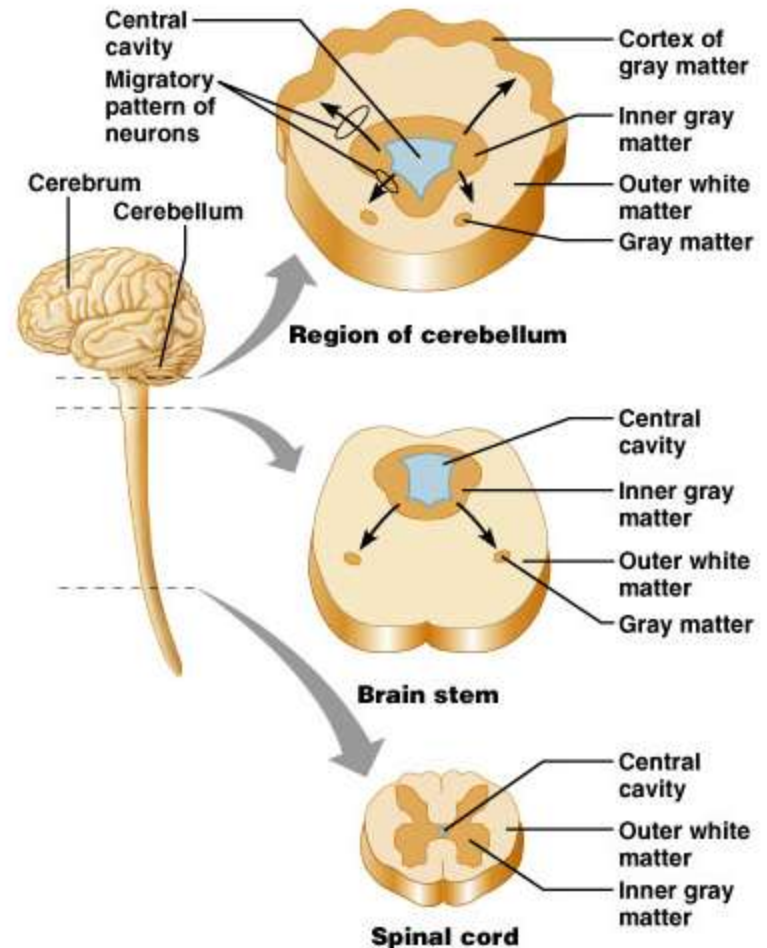
- White exterior to gray _____
- Gray surrounds hollow central cavity _____
- Two regions with additional gray called “cortex” _____
 - Cerebrum: “cerebral cortex”
 - Cerebellum: “cerebellar cortex”



Gray and White Matter

- Like spinal cord but with another layer of gray outside the white
 - Called **cortex**
 - Cerebrum and cerebellum have
- Inner gray: “**brain nuclei**” (not cell nuclei)
 - Clusters of cell bodies

Remember, in PNS clusters of cell bodies were called “ganglia”



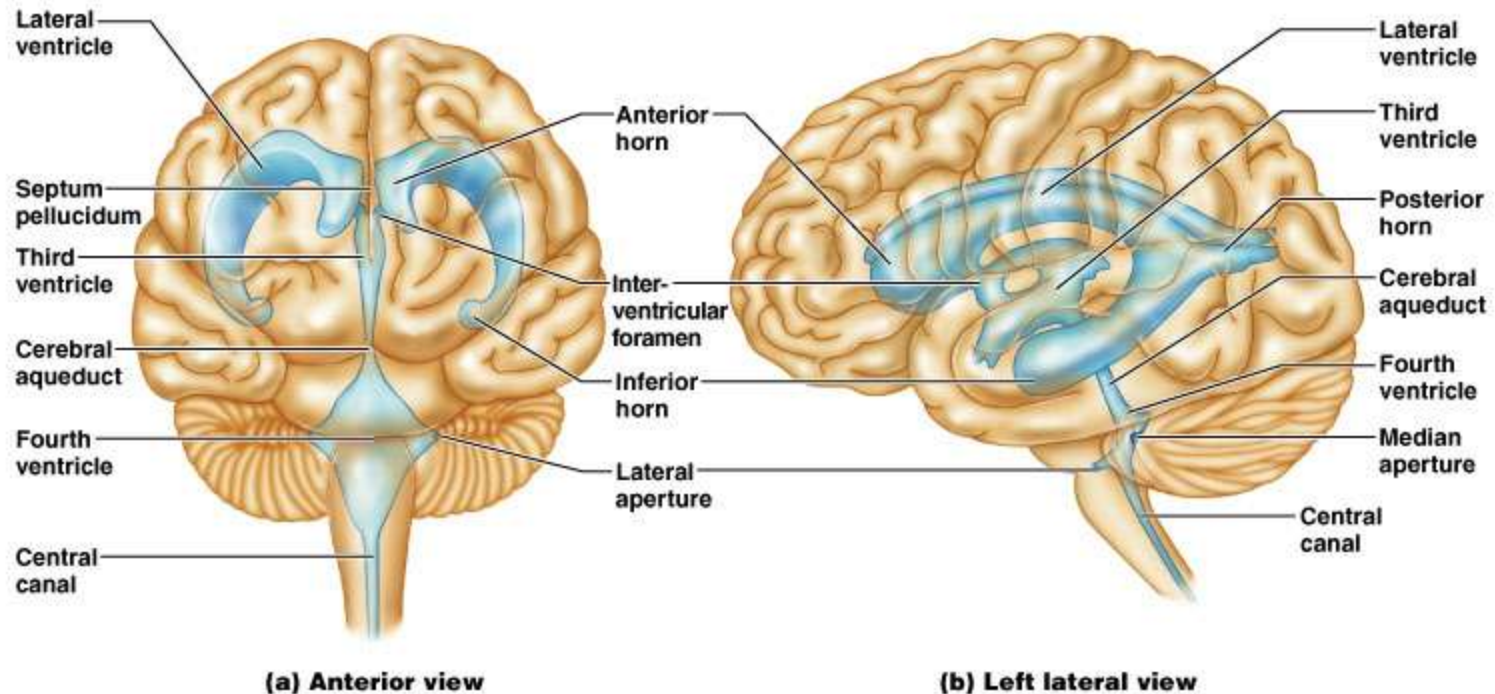
More words: brains stem is **caudal** (toward tail) to the more **rostral** (noseward) cerebrum

Ventricles

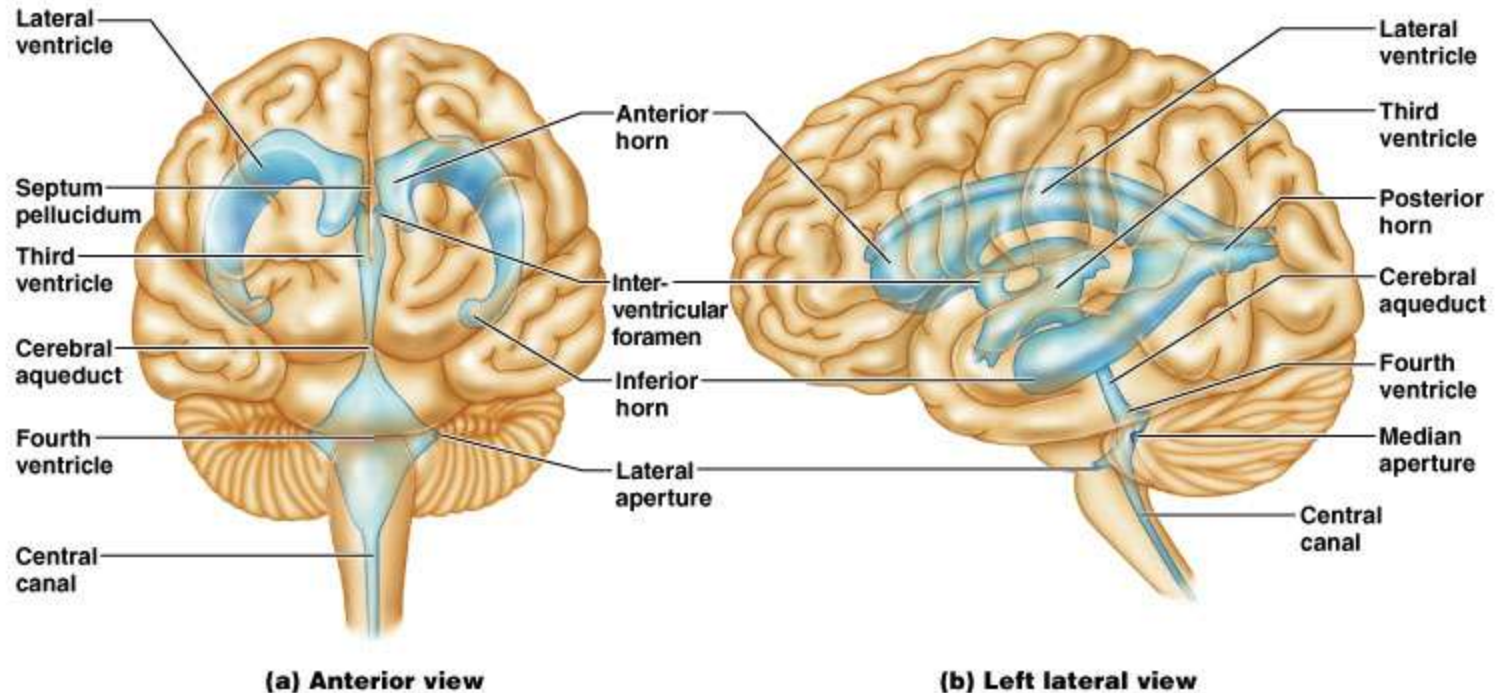
- Central cavities expanded
- Filled with **CSF** (cerebrospinal fluid)
- Lined by ependymal cells (these cells lining the choroid plexus make the CSF: see later slides)
- Continuous with each other and central canal of spinal cord

In the following slides, the ventricles are the parts colored blue

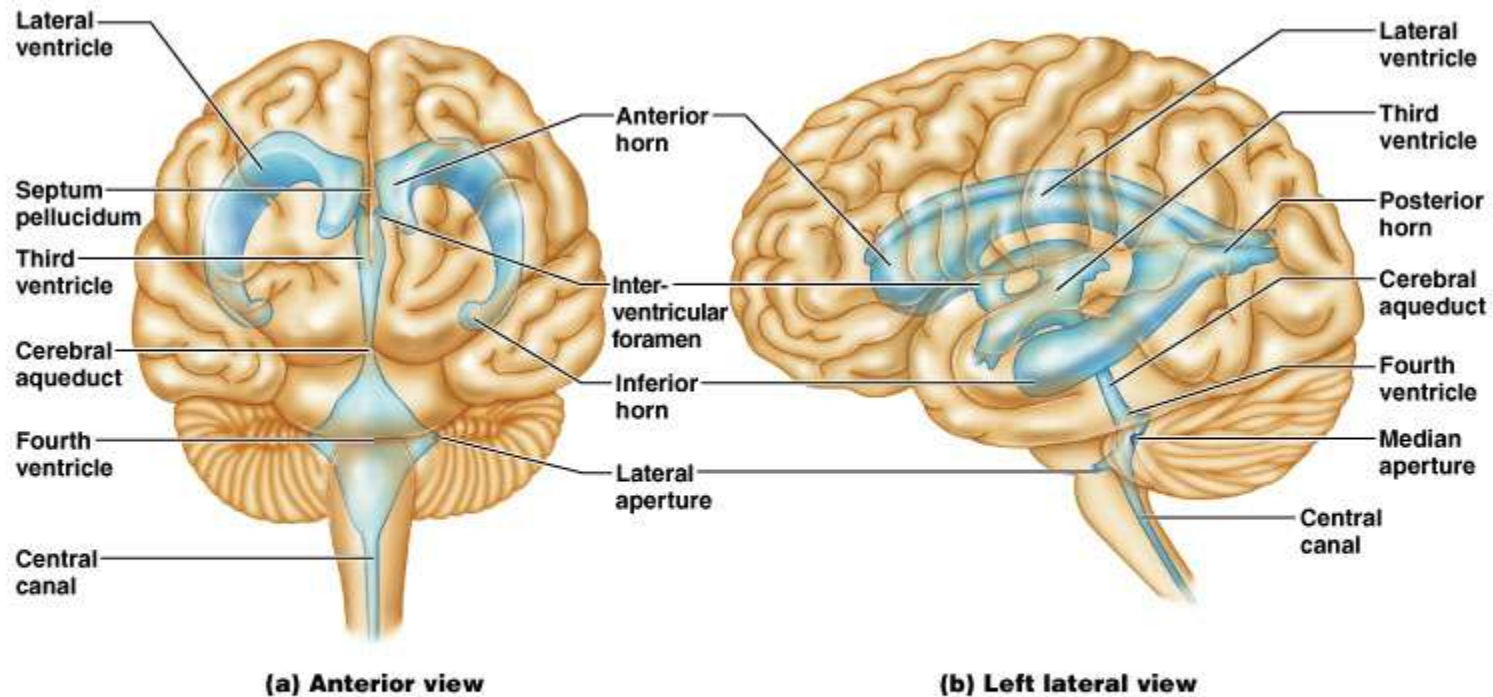
- Lateral ventricles
 - Paired, horseshoe shape
 - In cerebral hemispheres
 - Anterior are close, separated only by thin *Septum pellucidum*



- Third ventricle
 - In diencephalon
 - Connections
 - Interventricular foramen
 - Cerebral aqueduct



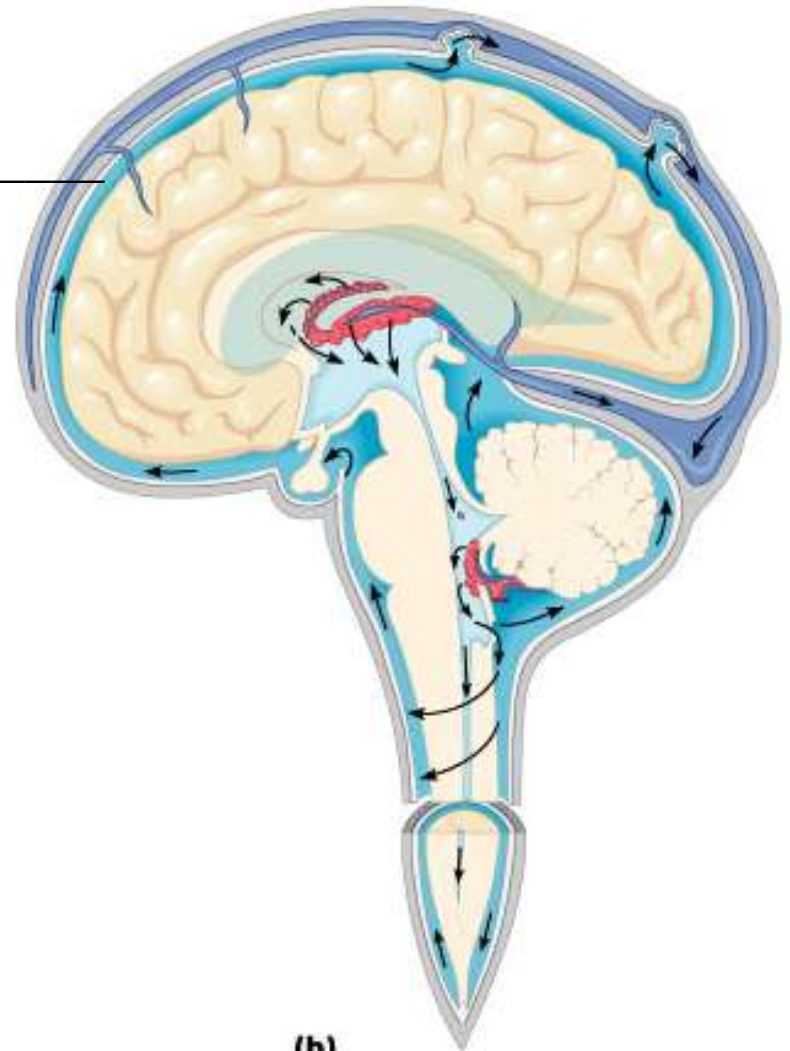
- Fourth ventricle
 - In the brainstem
 - Dorsal to pons and top of medulla
 - Holes connect it with subarachnoid space



Subarachnoid space

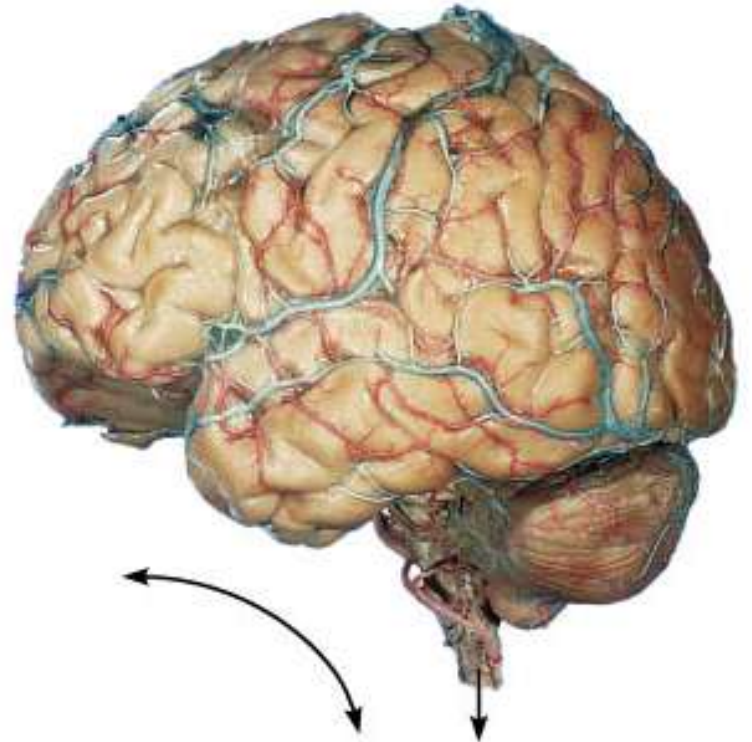
- Aqua blue in this pic
- Under thick coverings of brain
- Filled with CSF also
- Red: choroid plexus

(more later)

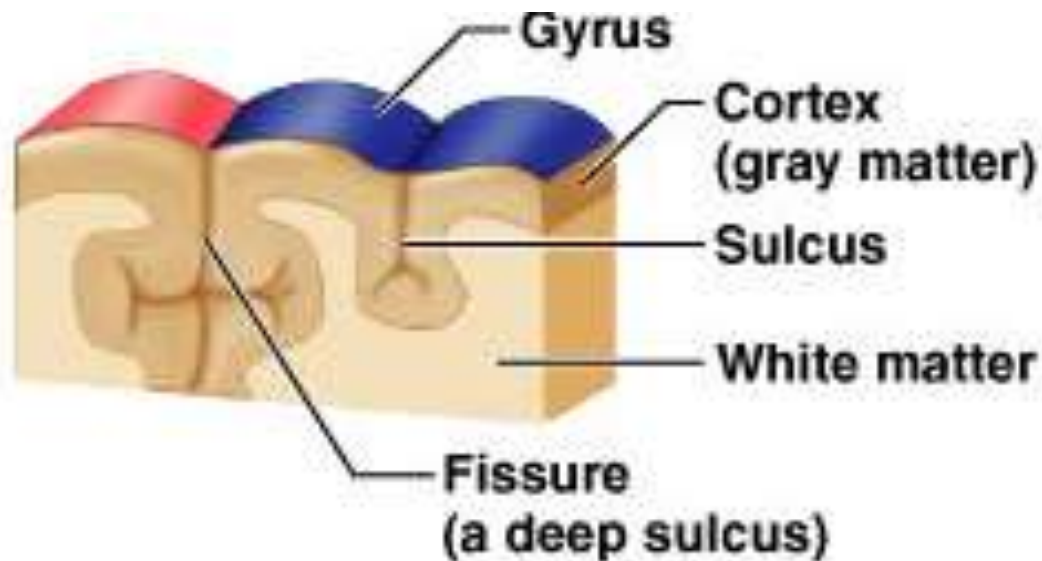


Surface anatomy

- ***Gyri*** (plural of ***gyrus***)
 - Elevated ridges
 - Entire surface
- Grooves separate gyri
 - A ***sulcus*** is a shallow groove (plural, ***sulci***)
 - Deeper grooves are ***fissures***

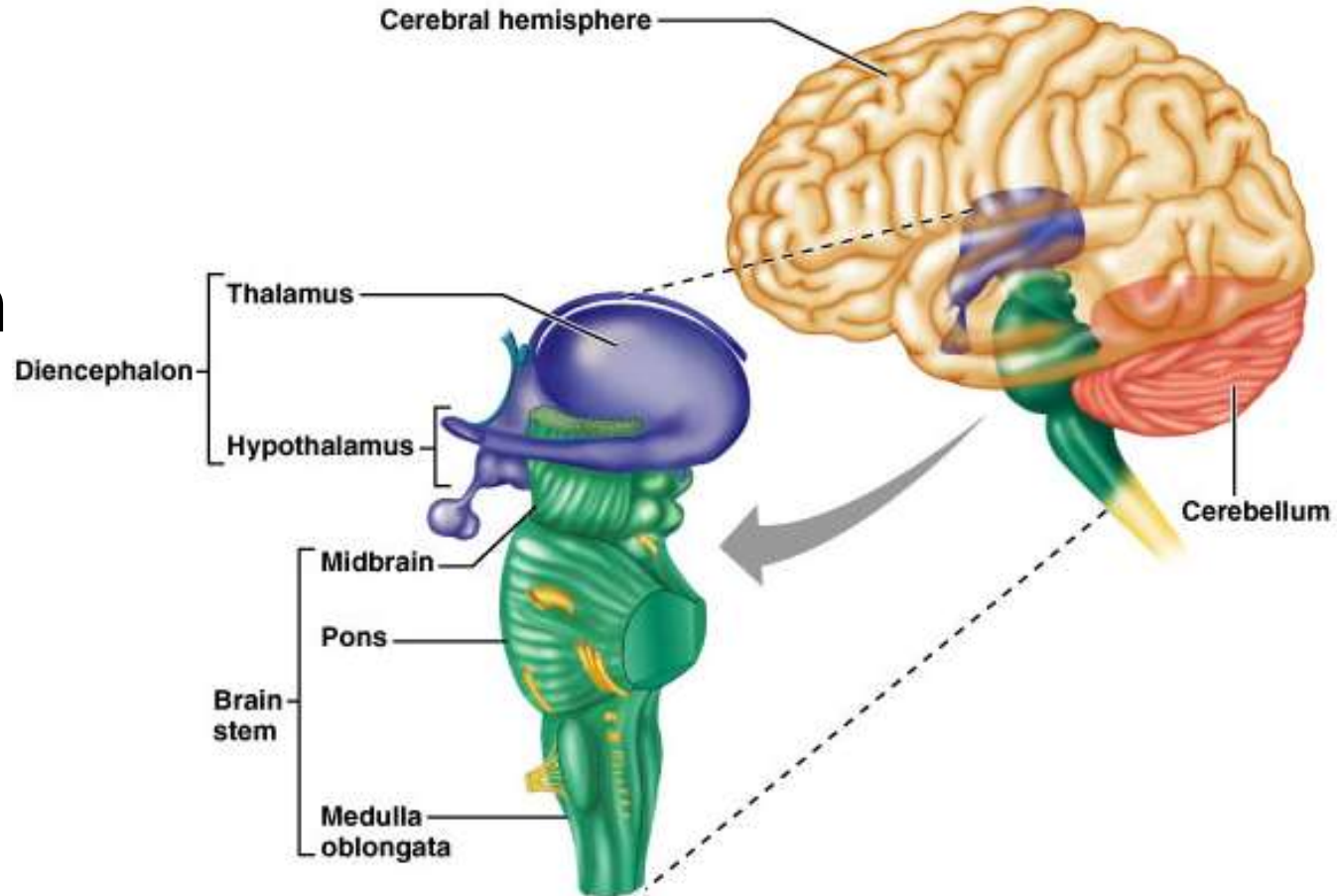


- ***Gyri*** (plural of ***gyrus***)
 - Elevated ridges
 - Entire surface
- Grooves separate gyri
 - A ***sulcus*** is a shallow groove (plural, ***sulci***)
 - Deeper grooves are ***fissures***



Parts of Brain

Cerebrum
Diencephalon
Brainstem
Cerebellum



simplified...

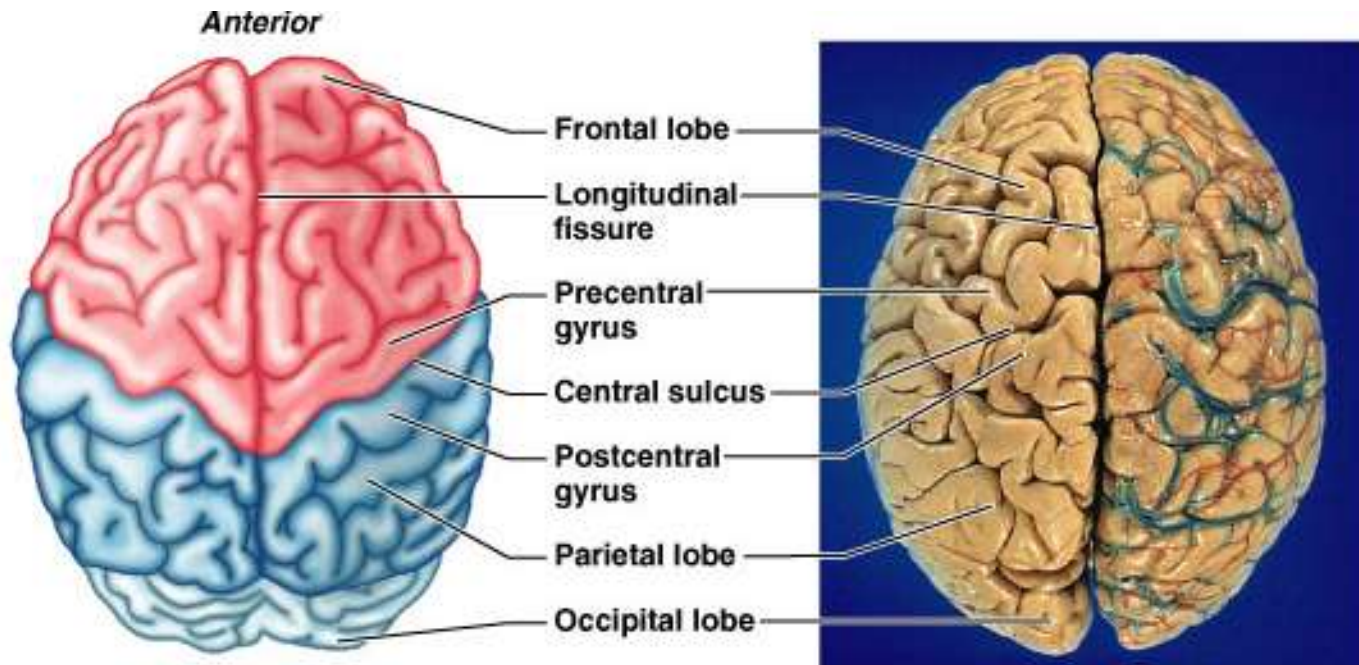
- Back of brain: perception
- Top of brain: movement
- Front of brain: thinking

Cerebral hemispheres

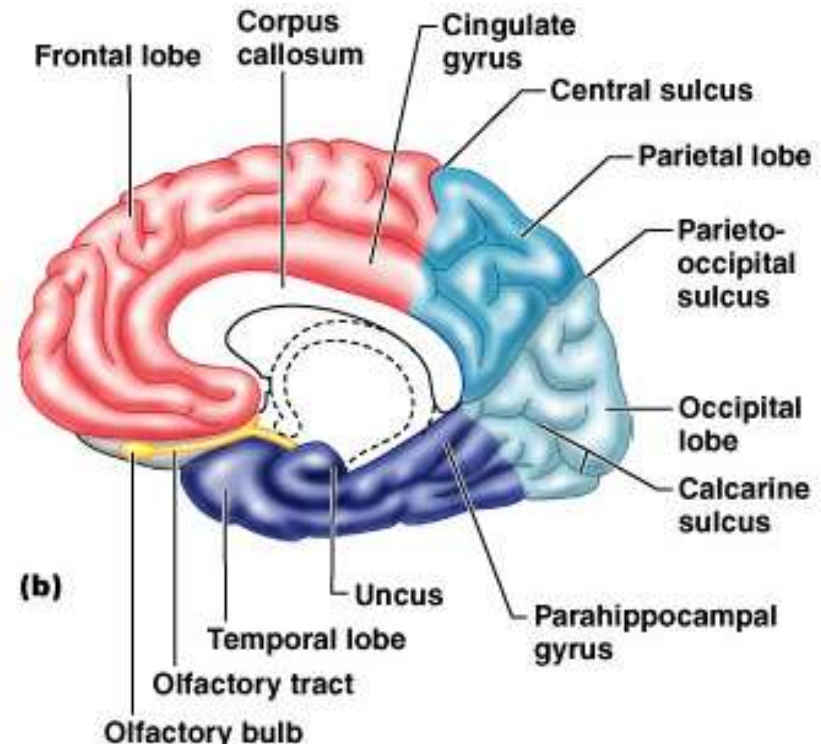
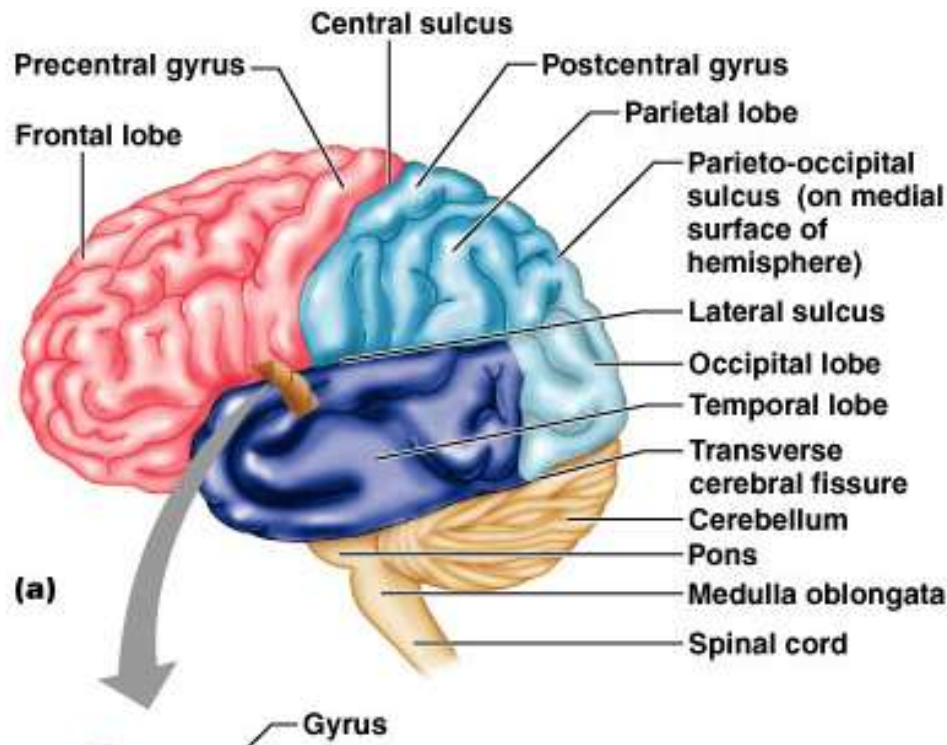
- Lobes: under bones of same name
 - Frontal
 - Parietal
 - Temporal
 - Occipital
 - Plus: Insula (buried deep in lateral sulcus)

Cerebral hemispheres: note lobes

- Divided by ***longitudinal fissure*** into right & left sides
- ***Central sulcus*** divides frontal from parietal lobes

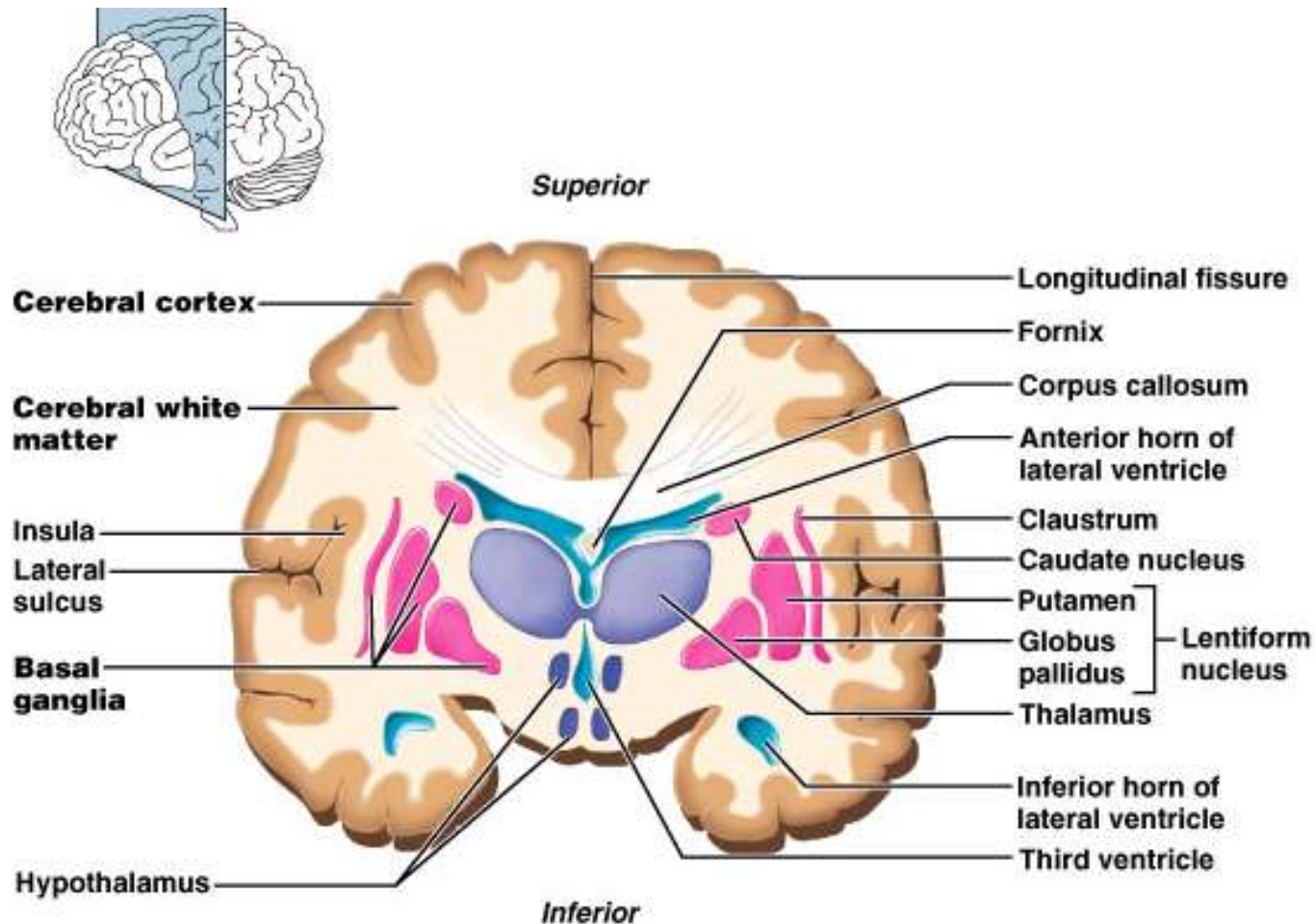


- ***Lateral sulcus*** separates temporal lobe from parietal lobe
- ***Parieto-occipital sulcus*** divides occipital and parietal lobes (not seen from outside)
- ***Transverse cerebral fissure*** separates cerebral hemispheres from cerebellum



coronal section

- Note: longitudinal fissure, lateral sulcus, insula
- Note: cerebral cortex (external sheet of gray), cerebral white, deep gray (basal ganglia)



Cerebral cortex

- Executive functioning capability
- Gray matter: of neuron cell bodies, dendrites, short unmyelinated axons
 - 100 billion neurons with average of 10,000 contacts each
- No fiber tracts (would be white)
- 2-4 mm thick (about 1/8 inch)
- Brodmann areas (historical: 52 structurally different areas given #s)
- Neuroimaging: functional organization (example later)

- Prenatal life: genes are responsible for creating the architecture of the brain
 - Cortex is the last to develop and very immature at birth
- Birth: excess of neurons but not inter-connected
 - 1st month of life: a million synapses/sec are made; this is genetic
- 1st 3 years of life: synaptic overgrowth (connections)
 - After this the density remains constant though some grow, some die
- Preadolescence: another increase in synaptic formation
- Adolescence until 25: brain becomes a reconstruction site
 - Connections important for self-regulation (in prefrontal cortex) are being remodeled: important for a sense of wholeness
 - Causes personal turbulence
 - Susceptible to stress and toxins (like alcohol and drugs) during these years; affects the rest of one's life
- The mind changes the brain (throughout life)
 - Where brain activation occurs, synapses happen
 - When pay attention & focus mind, neural firing occurs and brain structure changes (synapses are formed)
 - Human connections impact neural connections (ongoing experiences and learning include the interpersonal ones)

adapted from Dr. Daniel Siegel, UCLA

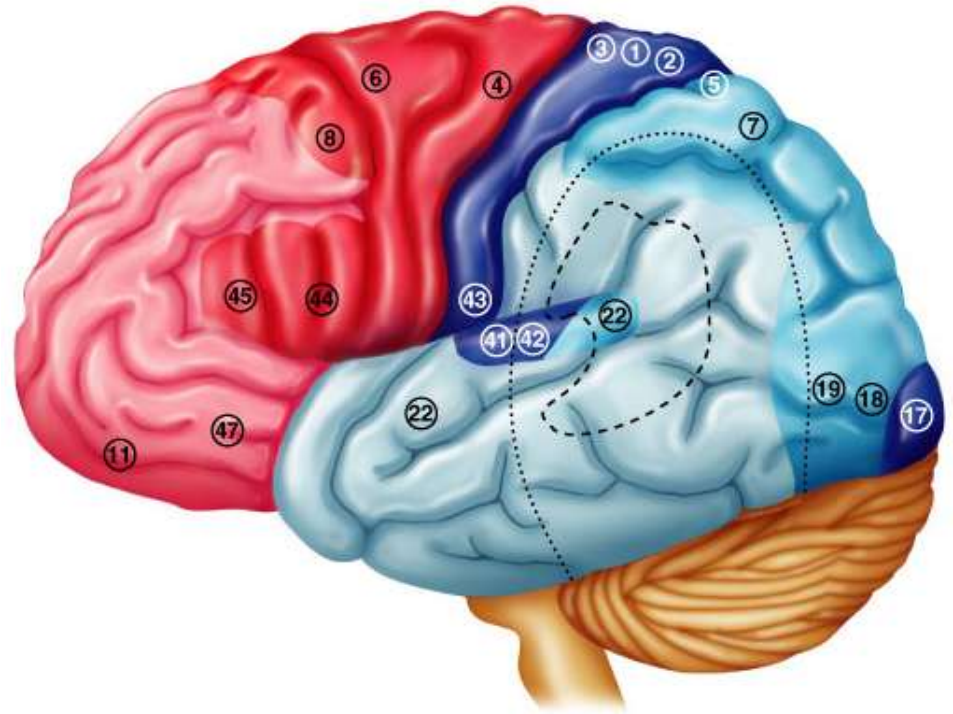
Cerebral cortex

- All the neurons are *interneurons*
 - By definition confined to the CNS
 - They have to synapse somewhere before the info passes to the peripheral nerves
- Three kinds of functional areas
 - ***Motor*** areas: movement
 - ***Sensory*** areas: perception
 - ***Association*** areas: integrate diverse information to enable purposeful action

Sensory areas

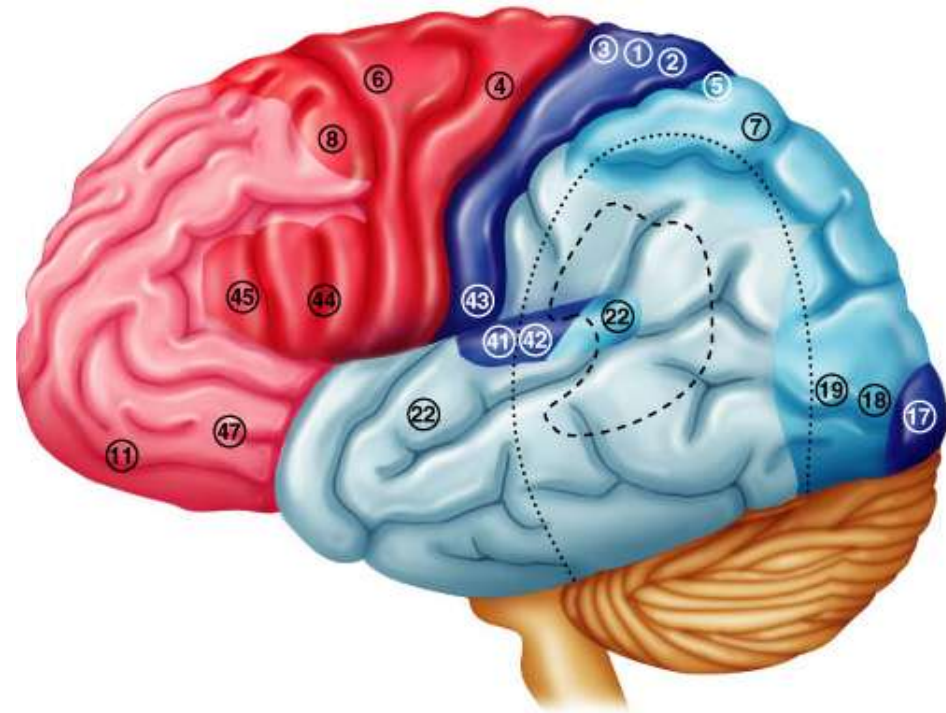
Posterior to central sulcus

- Primary somatosensory cortex: postcentral gyrus of parietal lobe (allows conscious awareness of sensation and the ability to localize it: *where* the sensation is from)
- Somatosensory association area: behind it (understanding of what is being felt: the *meaning* of it)

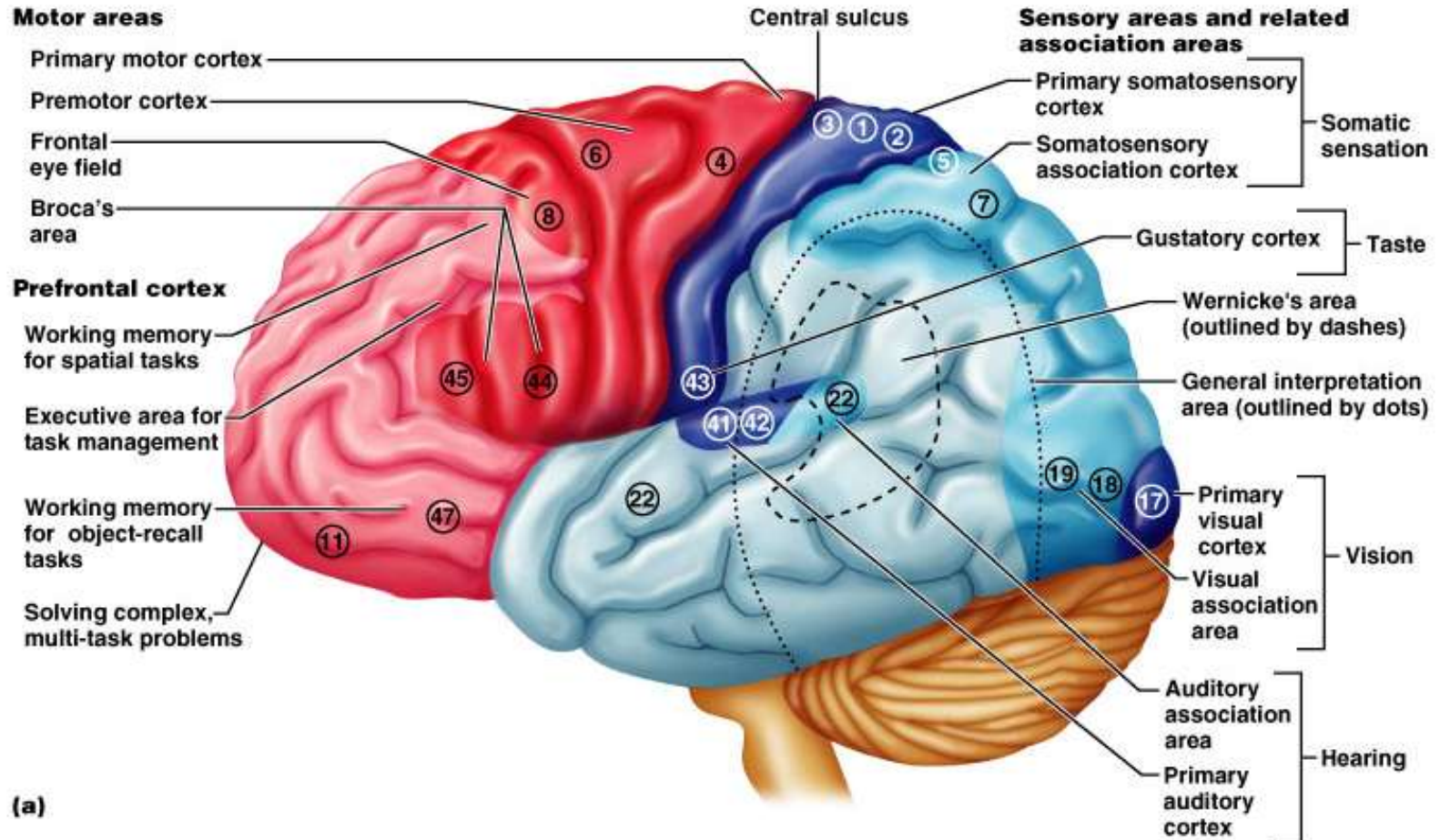


From special sense organs

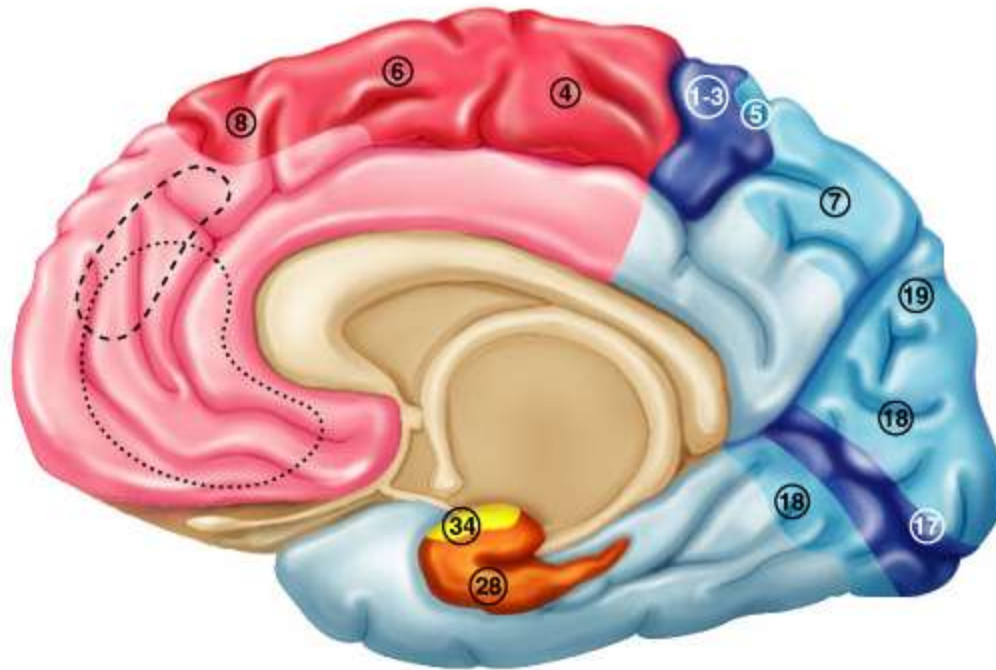
- Sight: occipital lobe
 - Primary visual cortex (17)
 - Handles info from contralateral retina (right $\frac{1}{2}$ of visual field is on left side)
 - Map of visual space
 - If damaged: functionally blind because no conscious awareness of sight
 - Visual association area (18 & 19)
 - Face recognition is usually on the right side
- Hearing: temporal lobe
 - Primary auditory area (41)
 - Auditory association area (22)



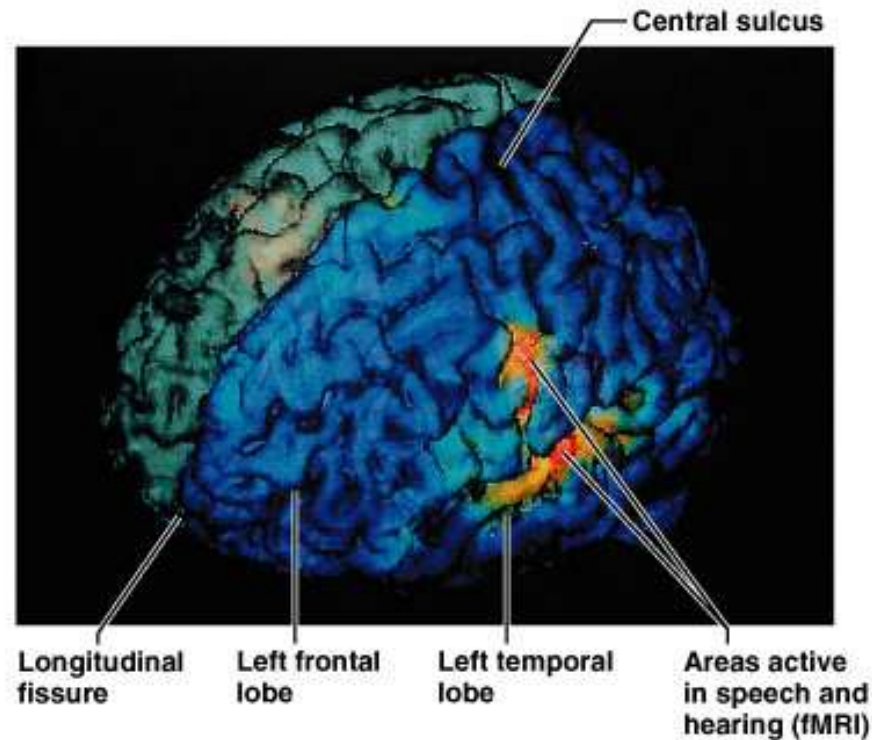
Refer back to this labeled version as needed



- Smell (olfactory sense): uncus
 - Deep in temporal lobe along medial surface



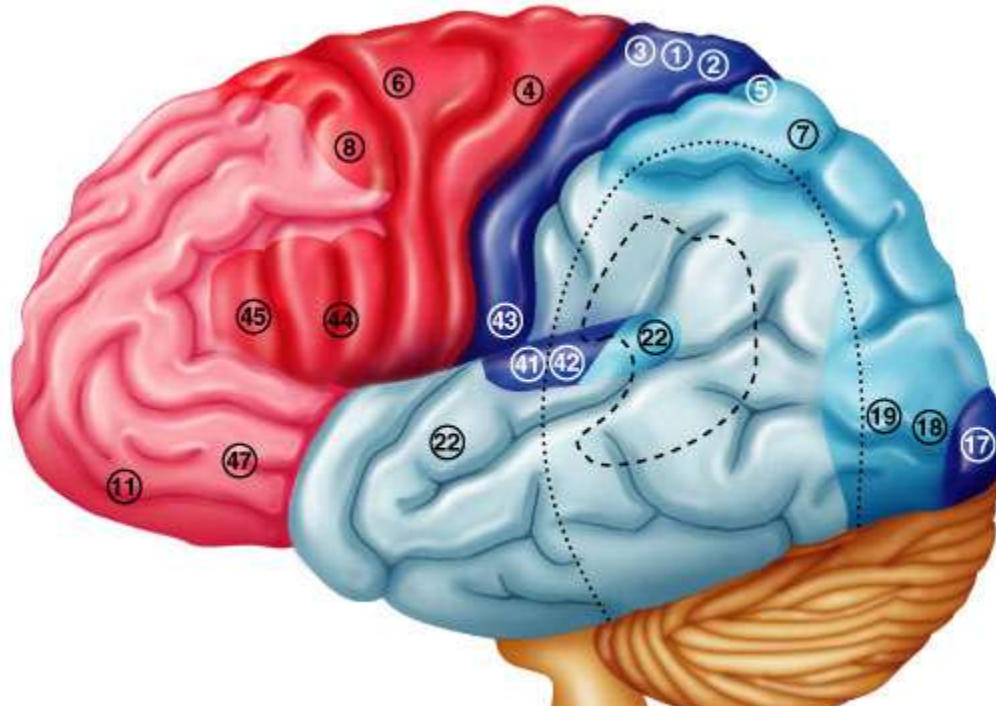
- fMRI: functional magnetic resonance imaging
- Cerebral cortex of person speaking & hearing
- Activity (blood flow) in posterior frontal and superior temporal lobes respectively



Motor areas

Anterior to central sulcus

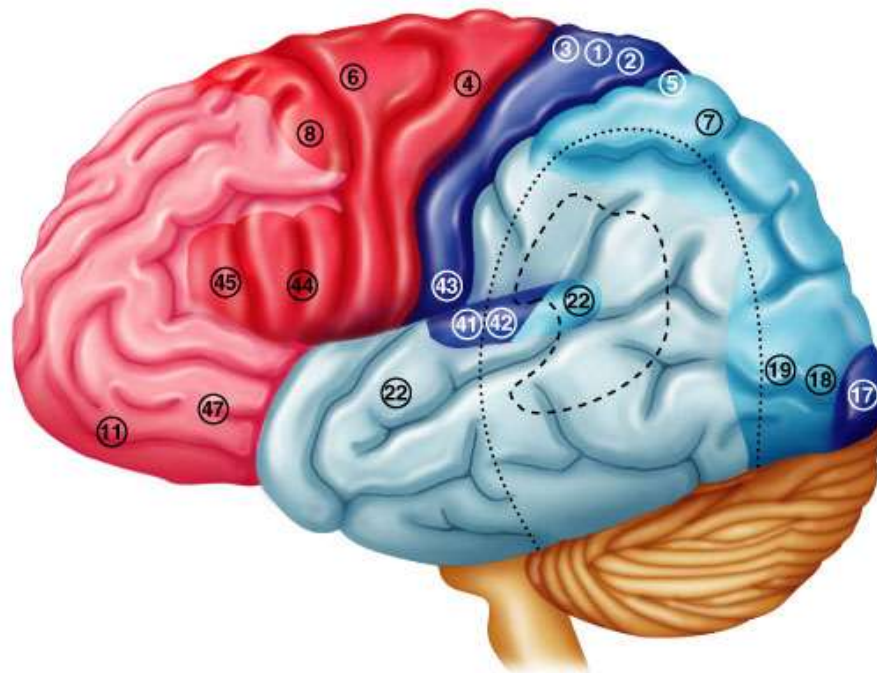
- Primary motor area
 - Precentral gyrus of frontal lobe (4)
 - Conscious or voluntary movement of skeletal muscles



- Primary motor area continued
 - Precentral gyrus of frontal lobe
 - Precise, conscious or voluntary movement of skeletal muscles
 - Large neurons called *pyramidal cells*
 - Their axons: form massive *pyramidal* or *corticospinal tracts*
 - Decend through brain stem and spinal cord
 - Cross to contralateral (the other) side in brainstem
 - **Therefore: right side of the brain controls the left side of the body, and the left side of the brain controls the right side of the body**

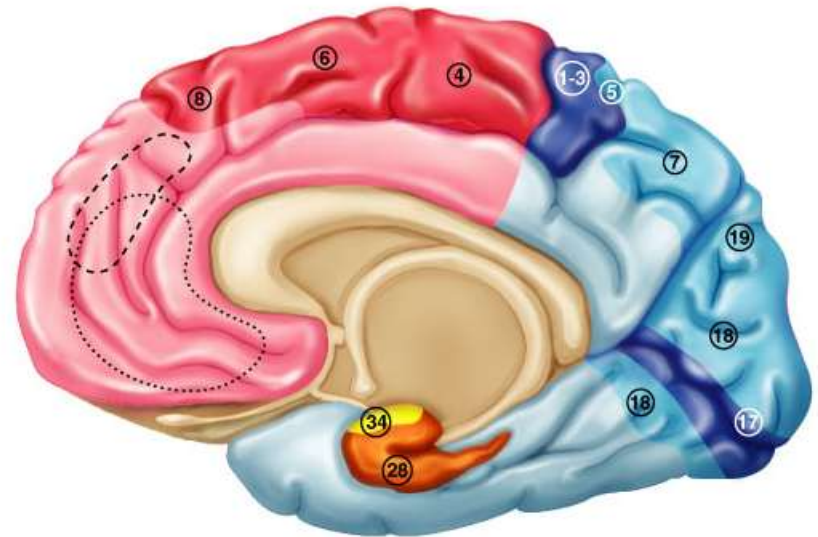
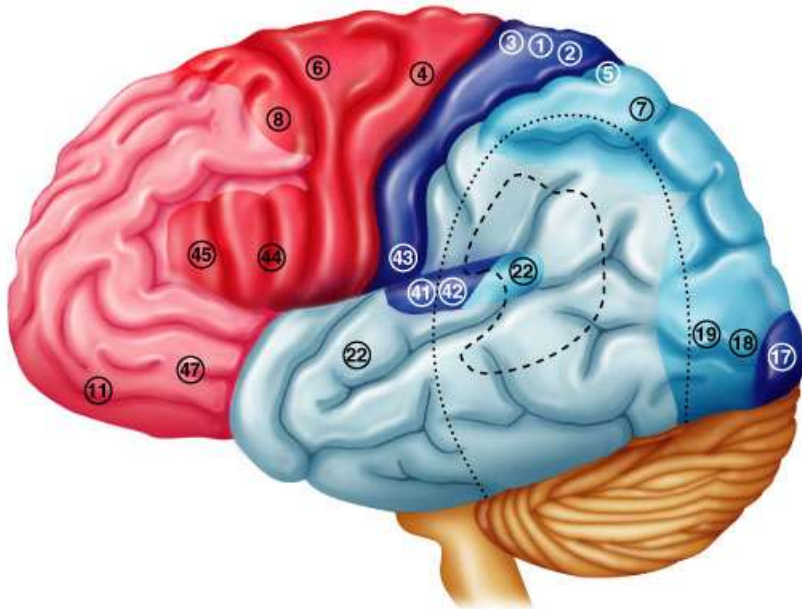
Motor areas – continued

- Broca's area (44): specialized motor speech area
 - Base of precentral gyrus just above lateral sulcus in only one hemisphere, usually left
 - Word articulation: the movements necessary for speech
 - Damage: can understand but can't speak; or if can still speak, words are right but difficult to understand



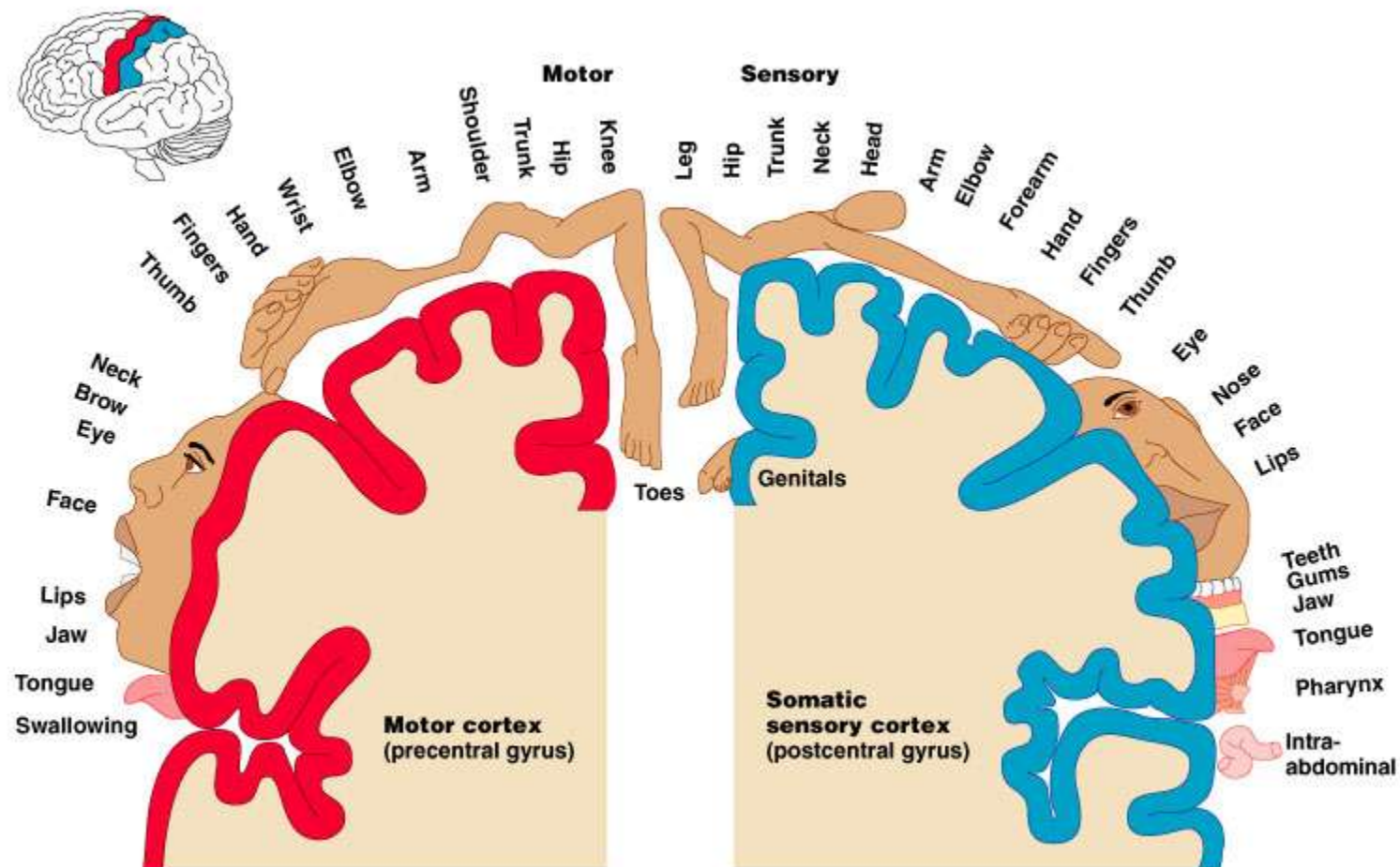
Motor areas – continued

- Premotor cortex (6): complex movements associated with highly processed sensory info; also planning of movements
- Frontal eye fields (inferior 8): voluntary movements of eyes



Homunculus – “little man”

- Body map: human body spatially represented
 - Where on cortex; upside down



Association Areas

Remember...

- Three kinds of functional areas (cerebrum)
 1. *Motor* areas: movement
 2. *Sensory* areas: perception
 3. ***Association*** areas: everything else

Association Areas

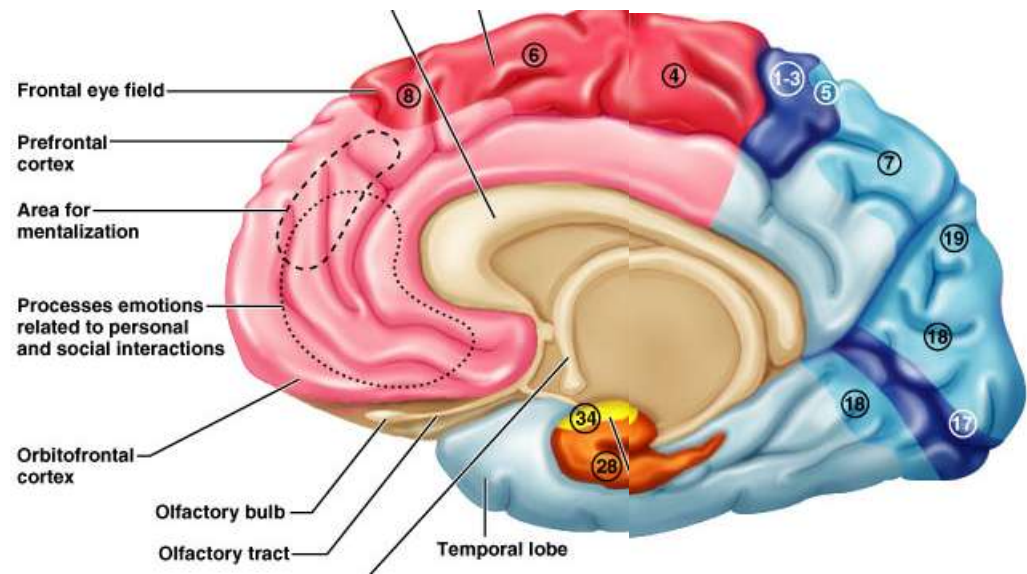
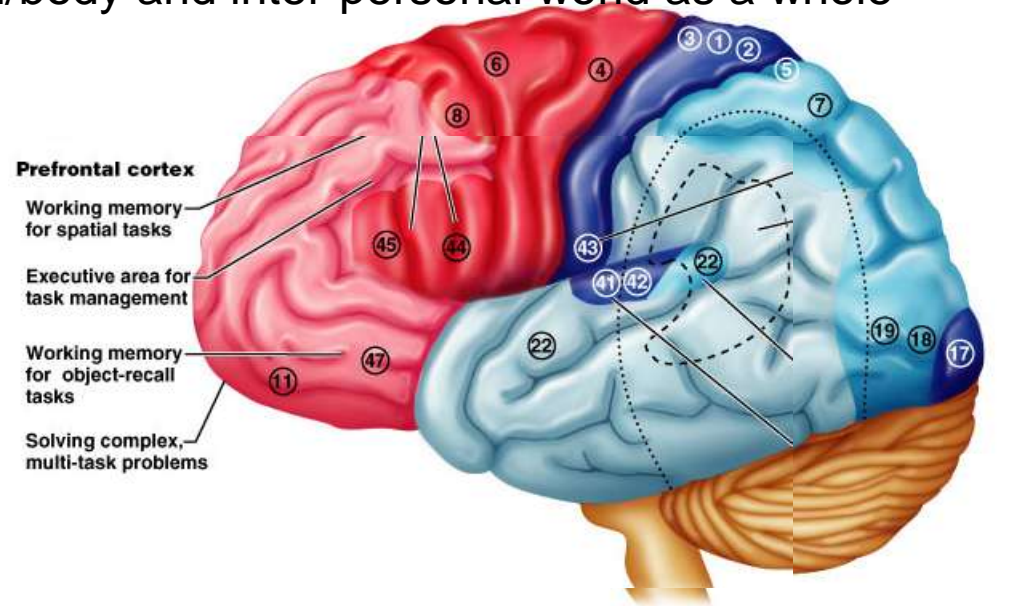
- Tie together different kinds of sensory input
- Associate new input with memories
- Is to be renamed “***higher-order processing***” areas

Prefrontal cortex: cognition

This area is remodeled during adolescence until the age of 25 and is very important for well-being; it coordinates the brain/body and inter-personal world as a whole

Intellect	Social skills
Abstract ideas	Appreciating humor
Judgment	Conscience
Personality	Mood
Impulse control	Mental flexibility
Persistence	Empathy
Complex Reasoning	
Long-term planning	

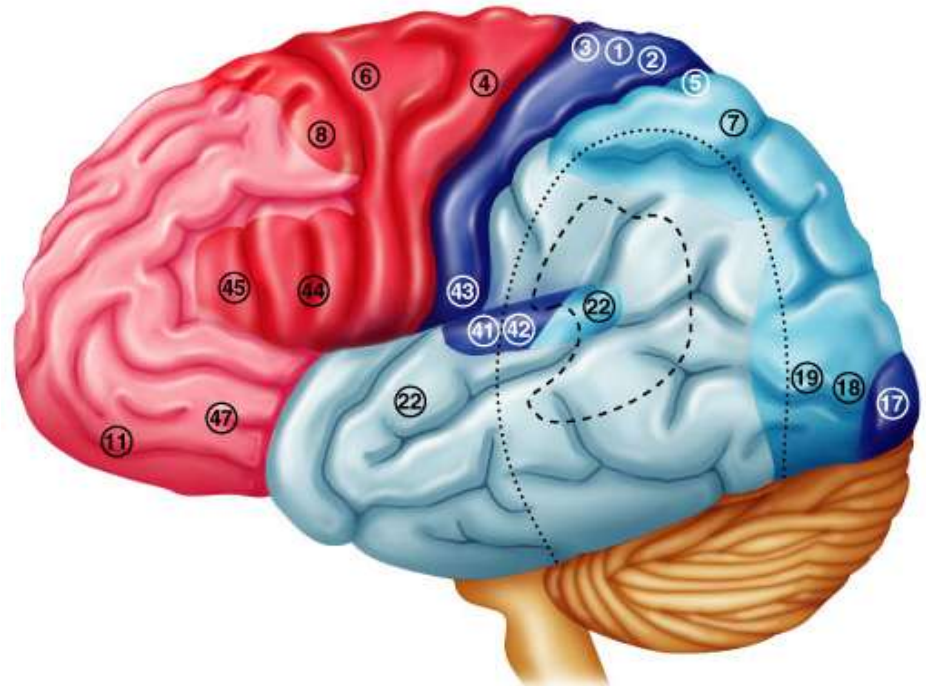
Executive functioning
e.g. multiple step problem solving
requiring temporary storage of
info (working memory)



Wernicke's area

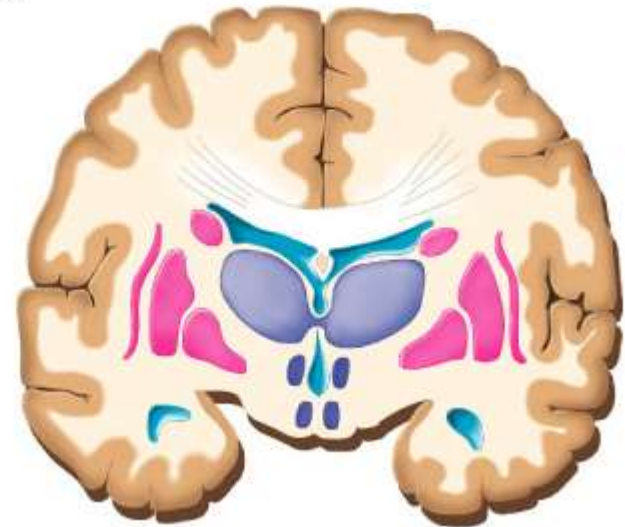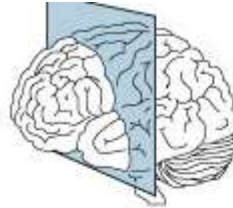
Region involved in recognizing and understanding spoken words

- Junction of parietal and temporal lobes
- One hemisphere only, usually left
- (Outlined by dashes)
- Pathology: comprehension impaired for written and spoken language: output fluent and voluminous but incoherent (words understandable but don't make sense; as opposed to the opposite with Broca's area)

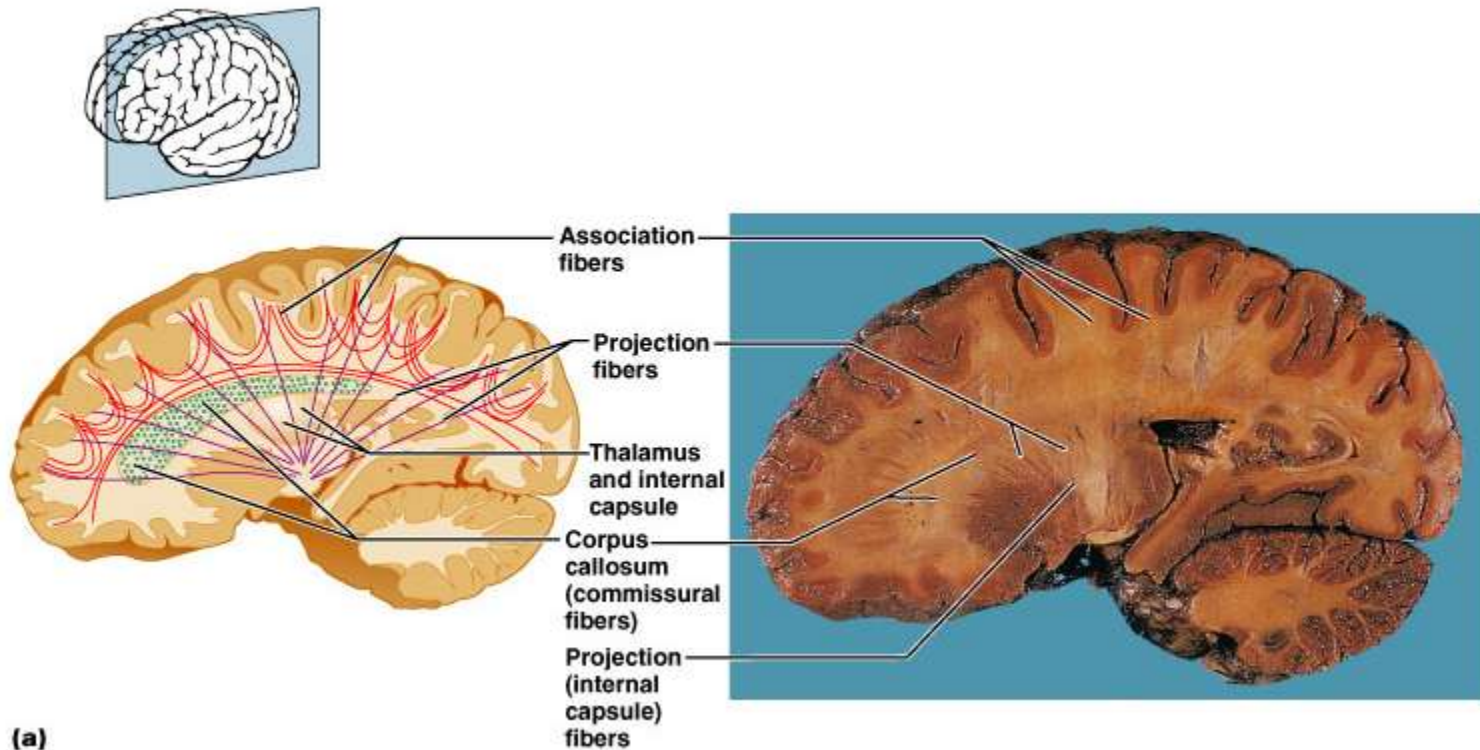


Cerebral white matter

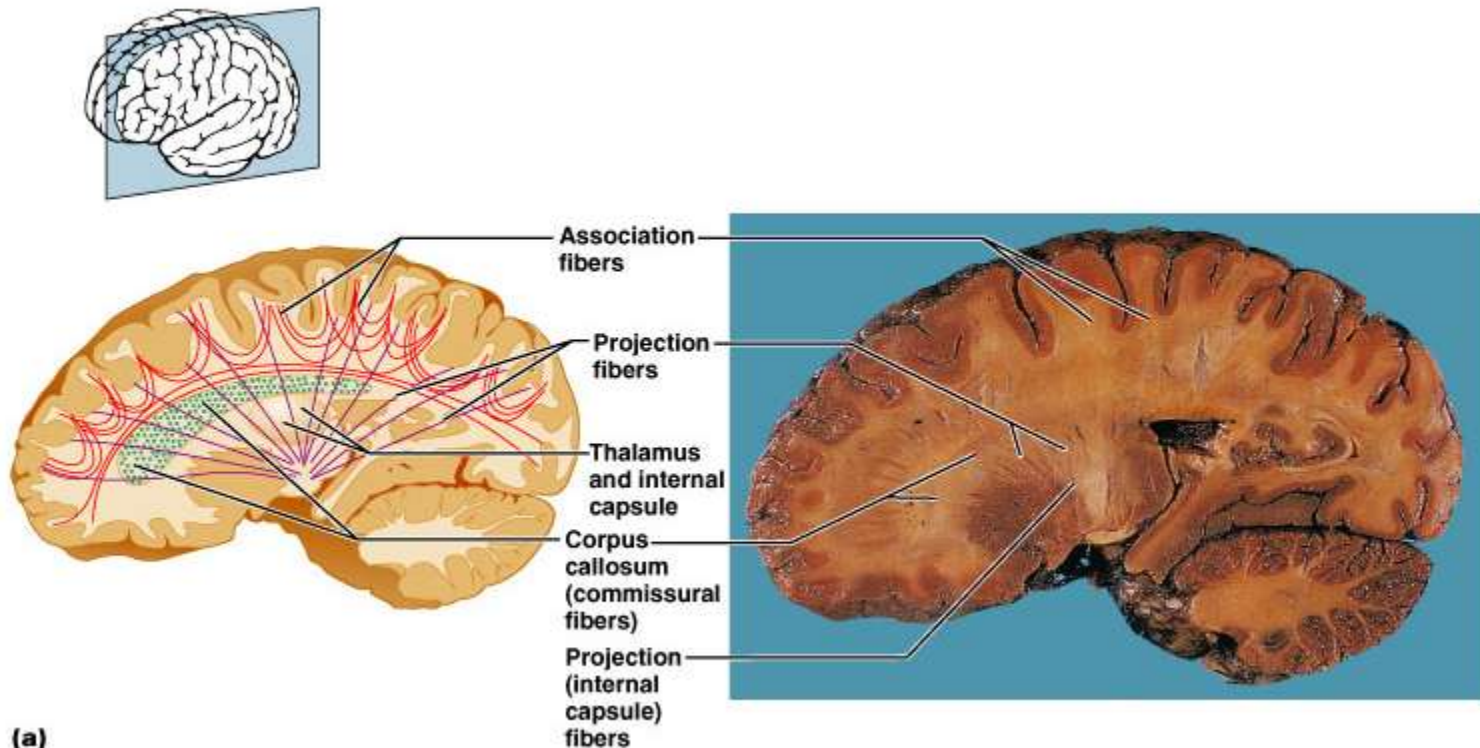
- Extensive communication
 - Areas of cortex with each other
 - Areas of cortex with brain stem and spinal cord
- Via (mostly) myelinated axon fibers bundled into tracts
 - Commissures
 - Association fibers
 - Projection fibers



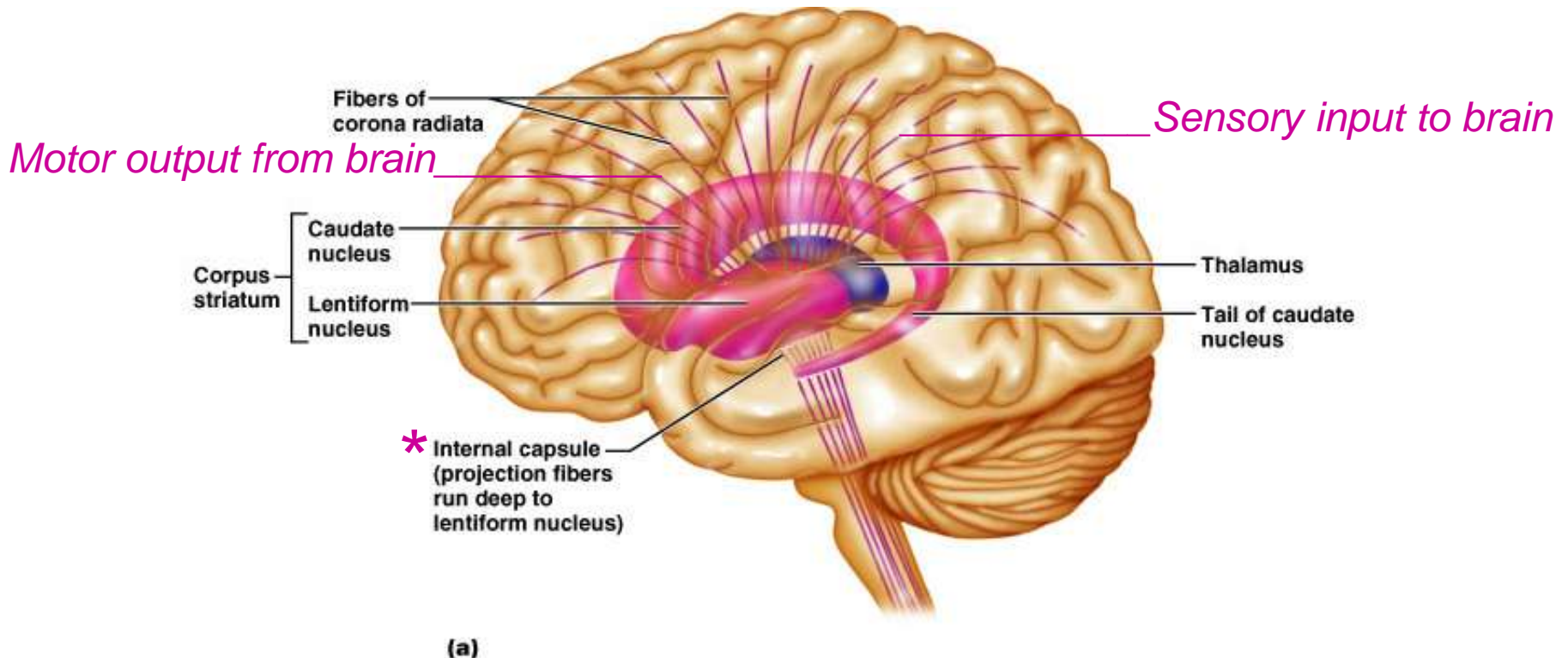
- **Commissures:** interconnect right and left hemispheres so can act as a whole
 - *Corpus callosum* is largest
- **Association fibers:** connect different parts of the *same* hemisphere; can be long or short



- **Projection fibers:** run *vertically*
 - Cerebral cortex running down (with motor instructions)
 - Or ascend to cerebral cortex from below (sensory info to cortex)

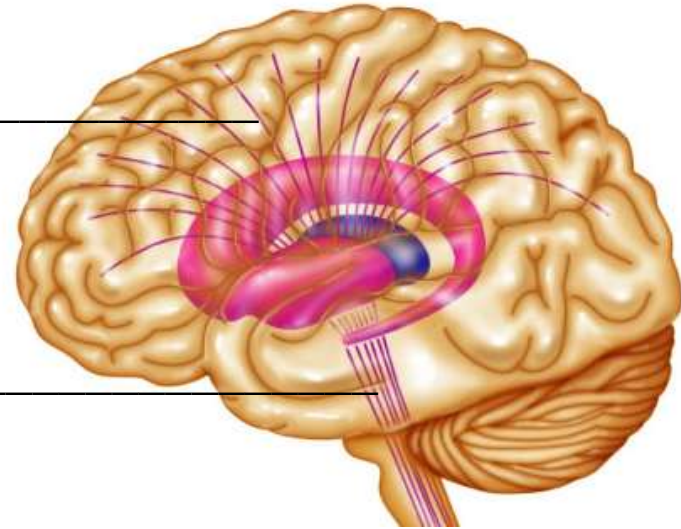


- **Corona radiata**: spray of projection fibers
 - From precentral (motor) gyrus
 - Combines with sensory fibers traveling to sensory cortex
 - Form a band of fibers called **internal capsule***



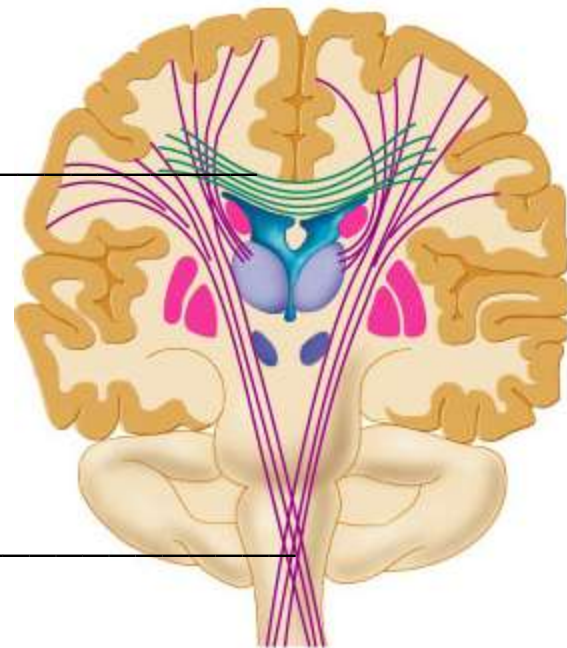
- Projection fibers

- Corona radiata: fanning out of the fibers
- Internal capsule: bundled, pass down



- Commisures

- Corpus callosum: connects right and left hemispheres

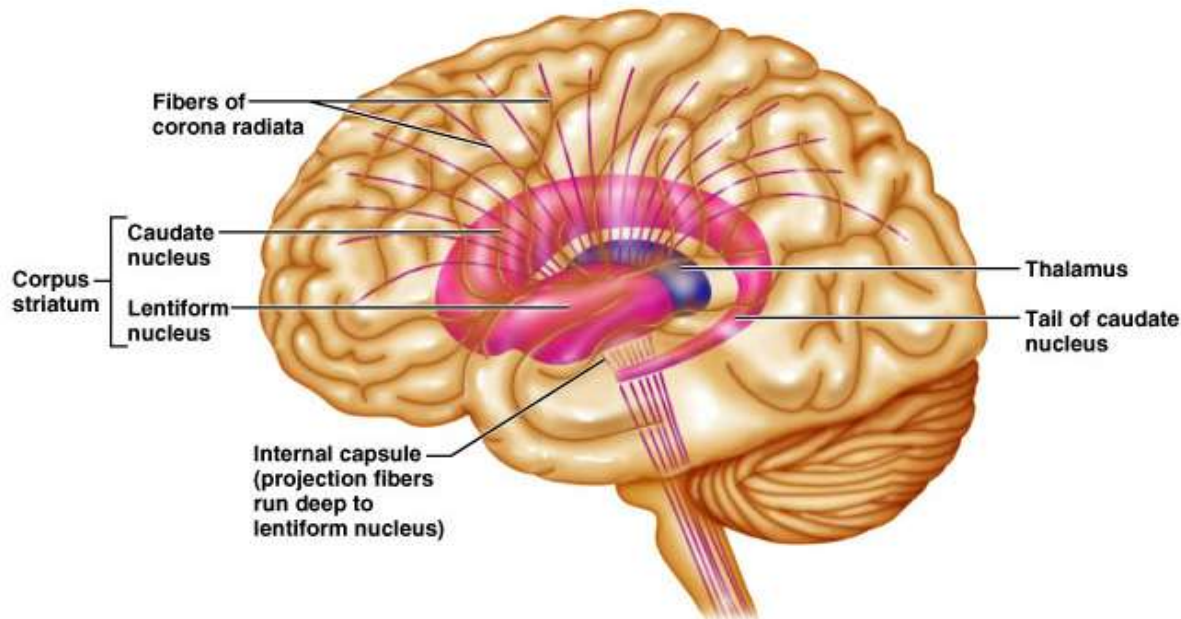


- Decussation: crossing of pyramidal tracts

- Cerebral hemisphere gray
 - Cortex – already reviewed
 - Basal forebrain nuclei: near hypothalamus - related to arousal, learning, memory and motor control
 - “Islands” of gray: **nuclei** (clusters of neuron cell bodies)

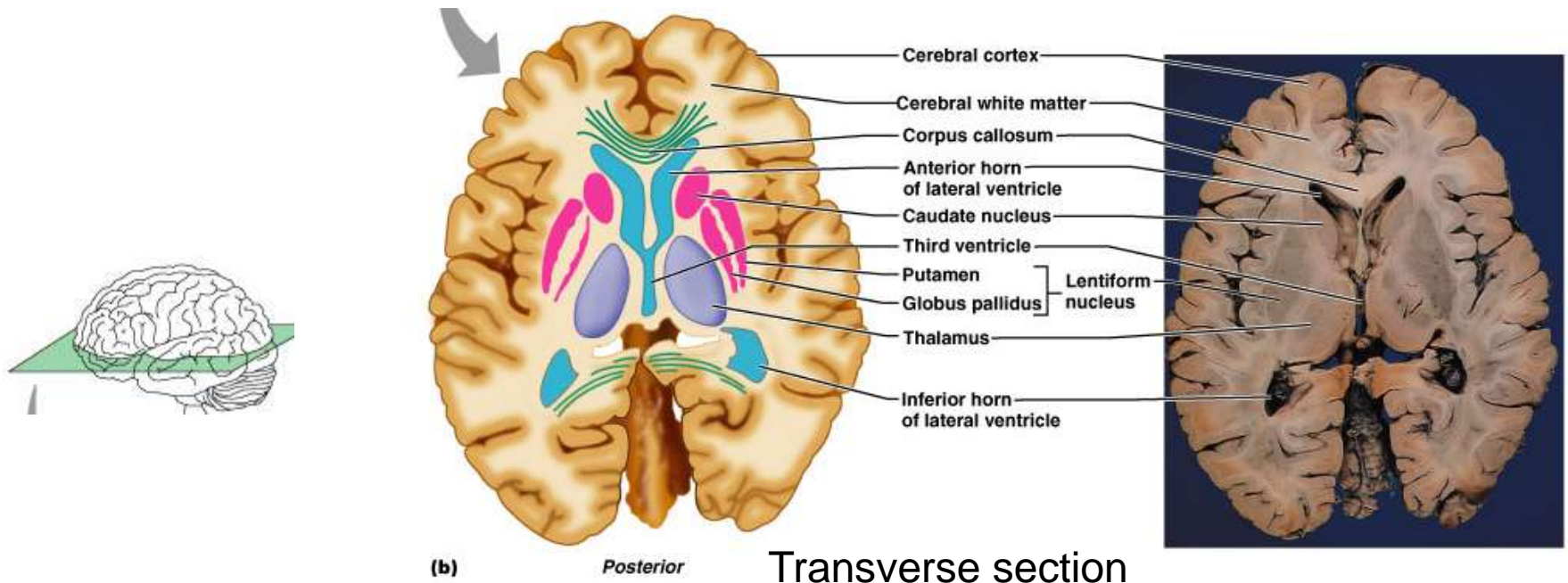
Important group is **basal ganglia**

(here “ganglia” *doesn't* refer to PNS cell bodies)

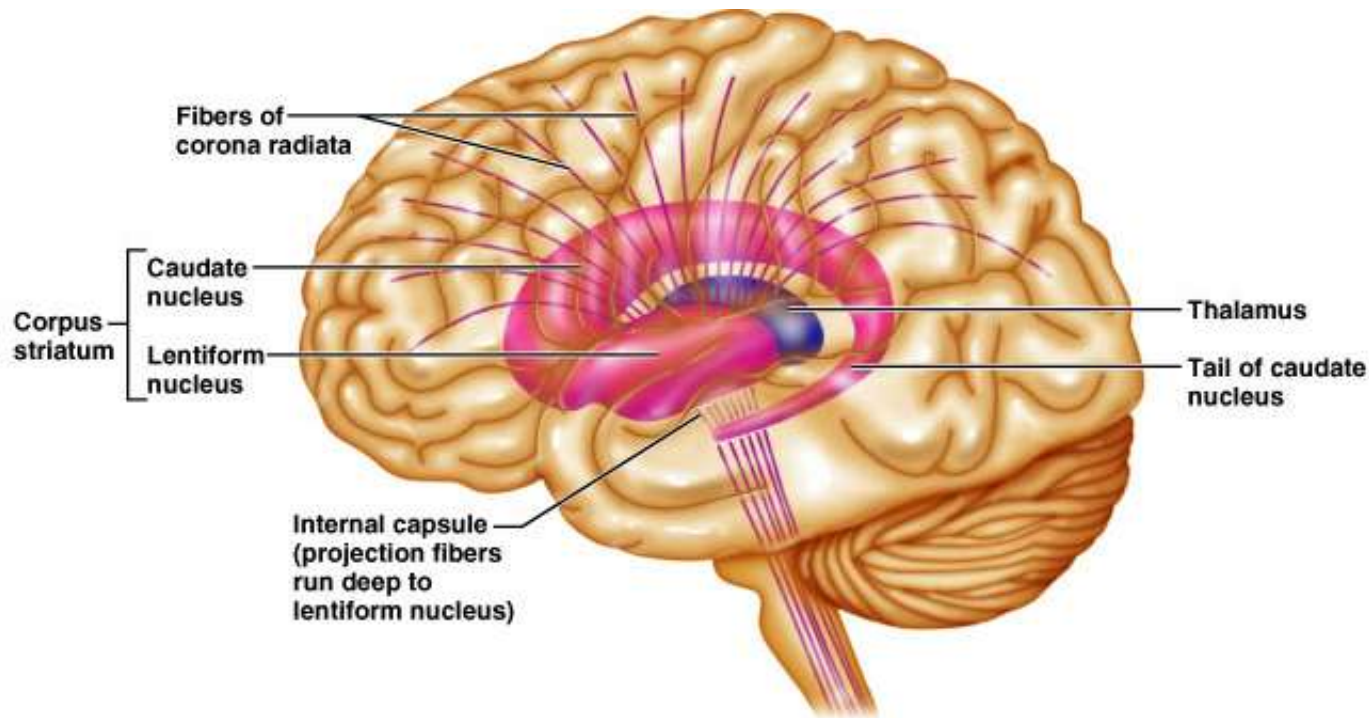


Basal ganglia

- Subcortical **motor** nuclei
- Part of “extrapyramidal system”
- Cooperate with cerebral cortex in controlling movements
- Most important ones: **caudate nucleus**, **lentiform nucleus** composed of **putamen** and **globus pallidus**
- Not part of basal forebrain nuclei (which are related to arousal, learning , memory and motor control)



- Internal capsule passes between diencephalon and basal ganglia to give them a striped appearance
 - **Caudate and lentiform** sometimes called ***corpus striatum*** because of this



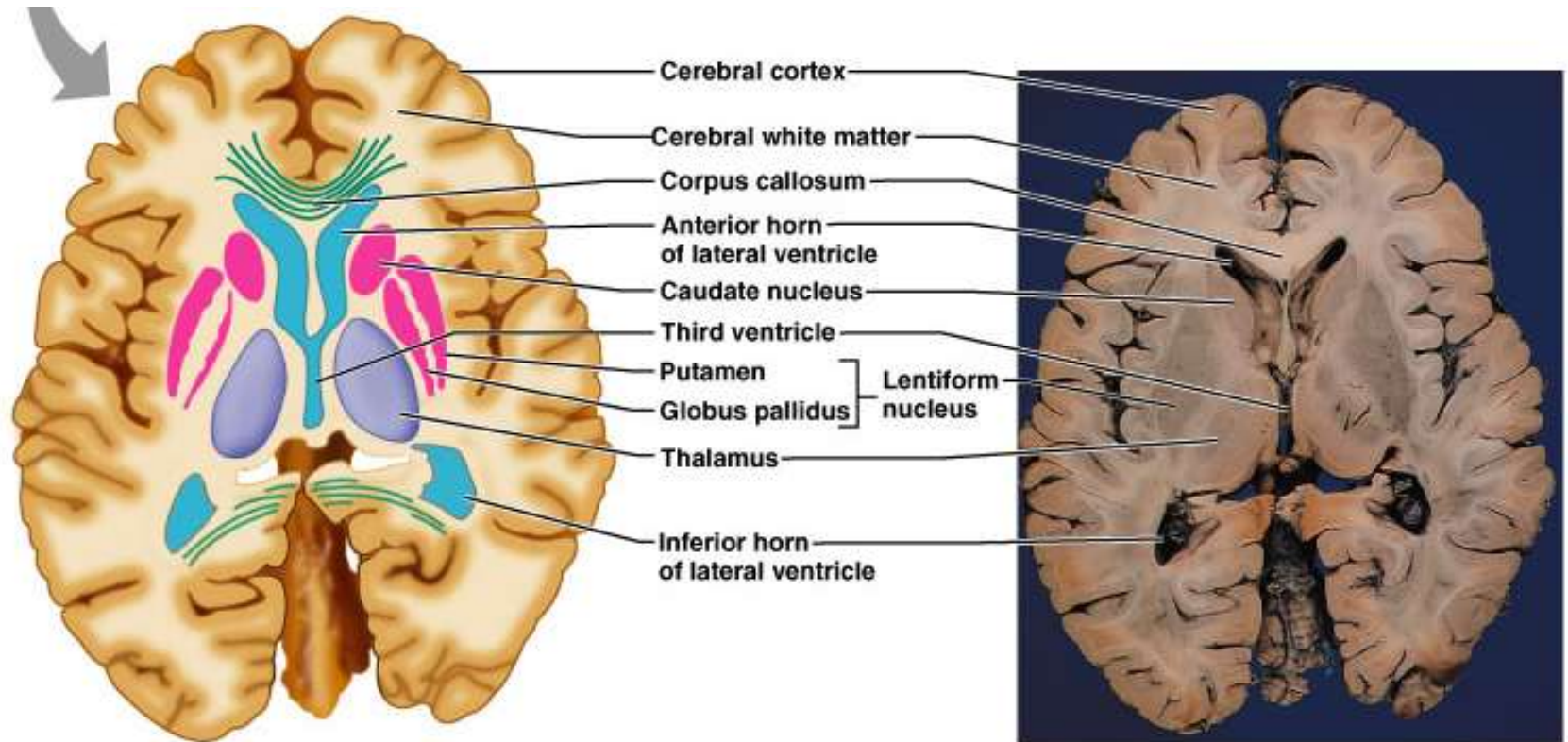
(a)

Basal ganglia

- Cooperate with cerebral cortex in controlling movements
- Communicate with cerebral cortex, receive input from cortical areas, send most of output back to motor cortex through thalamus
- Involved with stopping/starting & intensity of movements
- “Dyskinesias” – “bad movements”
 - Parkinson’s disease: loss of inhibition from substantia nigra of midbrain – everything slows down
 - Huntington disease: overstimulation (“choreoathetosis”) – degeneration of corpus striatum which inhibits; eventual degeneration of cerebral cortex (AD; genetic test available)
 - Extrapiramidal drug side effects: “tardive dyskinesia”
 - Can be irreversible; haloperidol, thiorazine and similar drugs

Basal ganglia

- Note relationship of basal ganglia to thalamus and ventricles



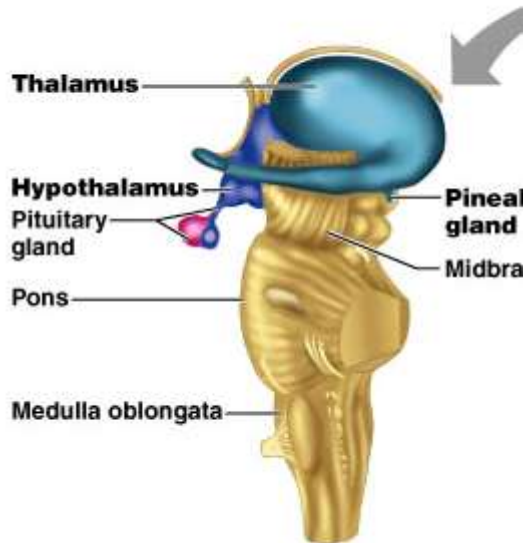
(b) Posterior

Transverse section again

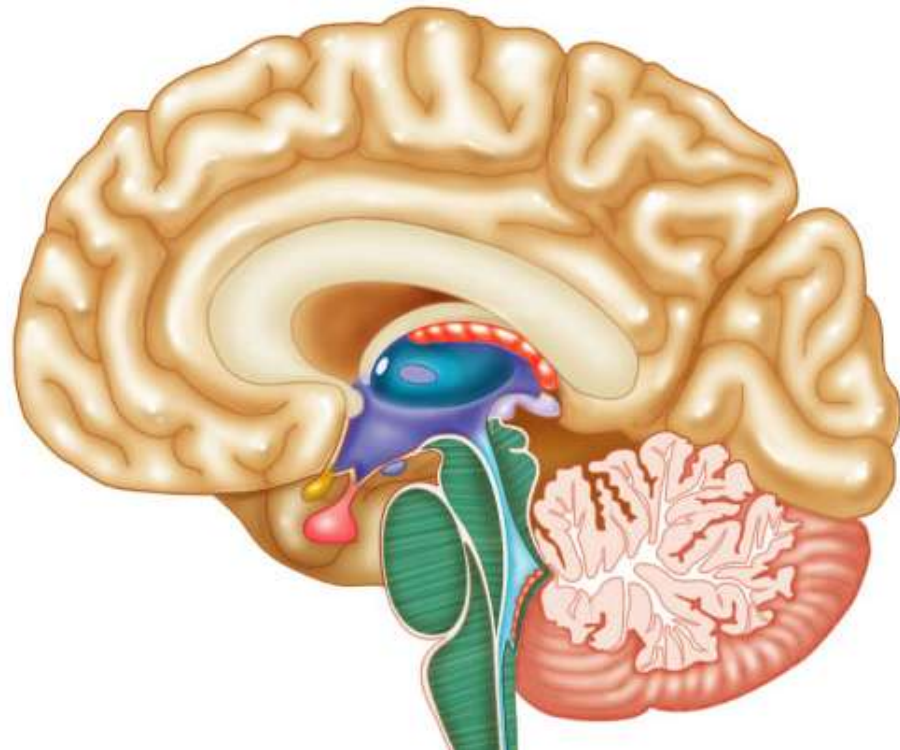
Diencephalon (part of forebrain)

Contains dozens of nuclei of gray matter

- Thalamus
- Hypothalamus
- Epithalamus (mainly pineal)

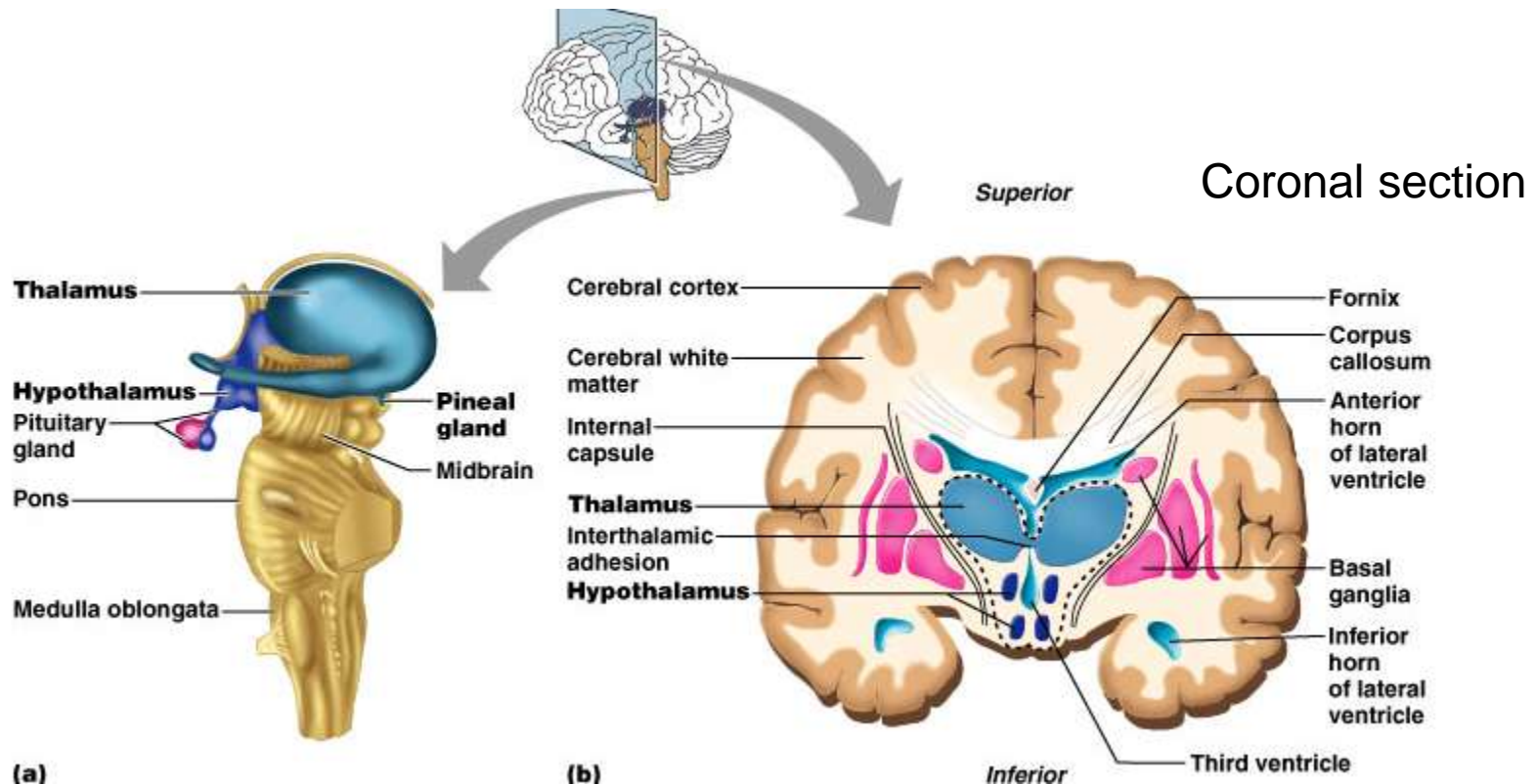


(a)



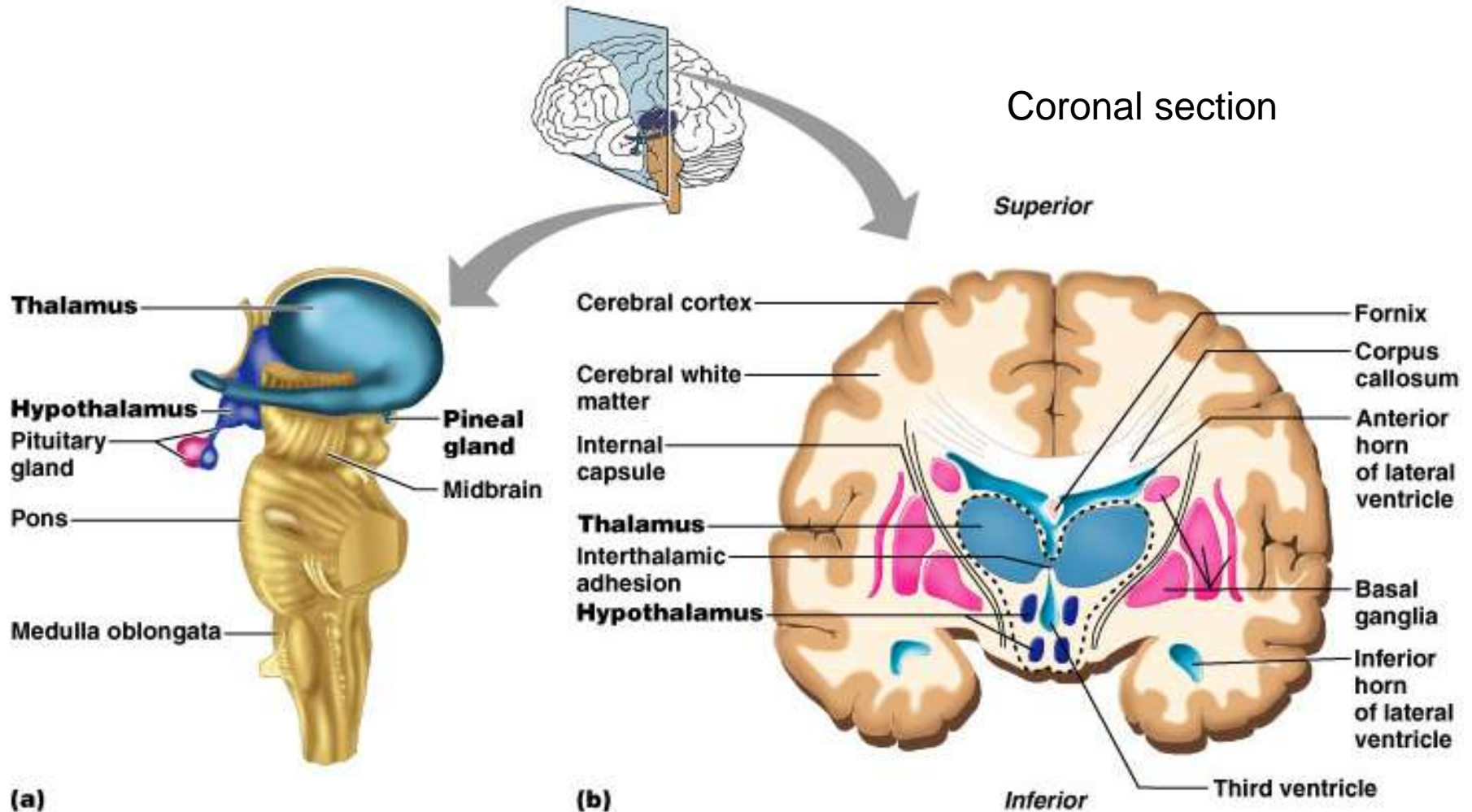
Thalamus (egg shaped; means inner room)

- Two large lobes of gray matter (over a dozen nuclei)
- Laterally enclose the 3rd ventricle
- Gateway to cerebral cortex: **every part of brain that communicates with cerebral cortex relays signals through a nucleus in the thalamus** (e.g. certain nucleus for info from retina, another from ears, etc.)
- Processing (editing) occurs also in thalamus



Hypothalamus

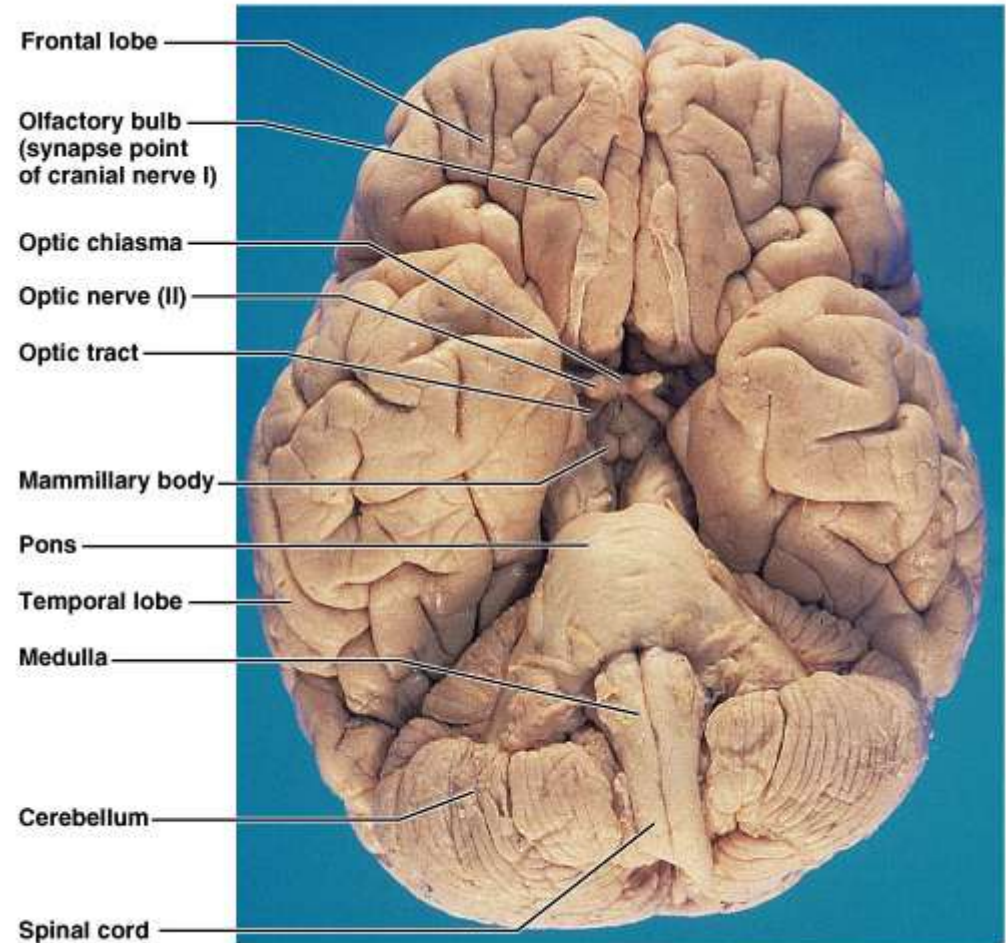
Forms inferolateral walls of 3rd ventricle
Many named nuclei



Diencephalon – surface anatomy

Hypothalamus is between optic chiasma to and including mamillary bodies

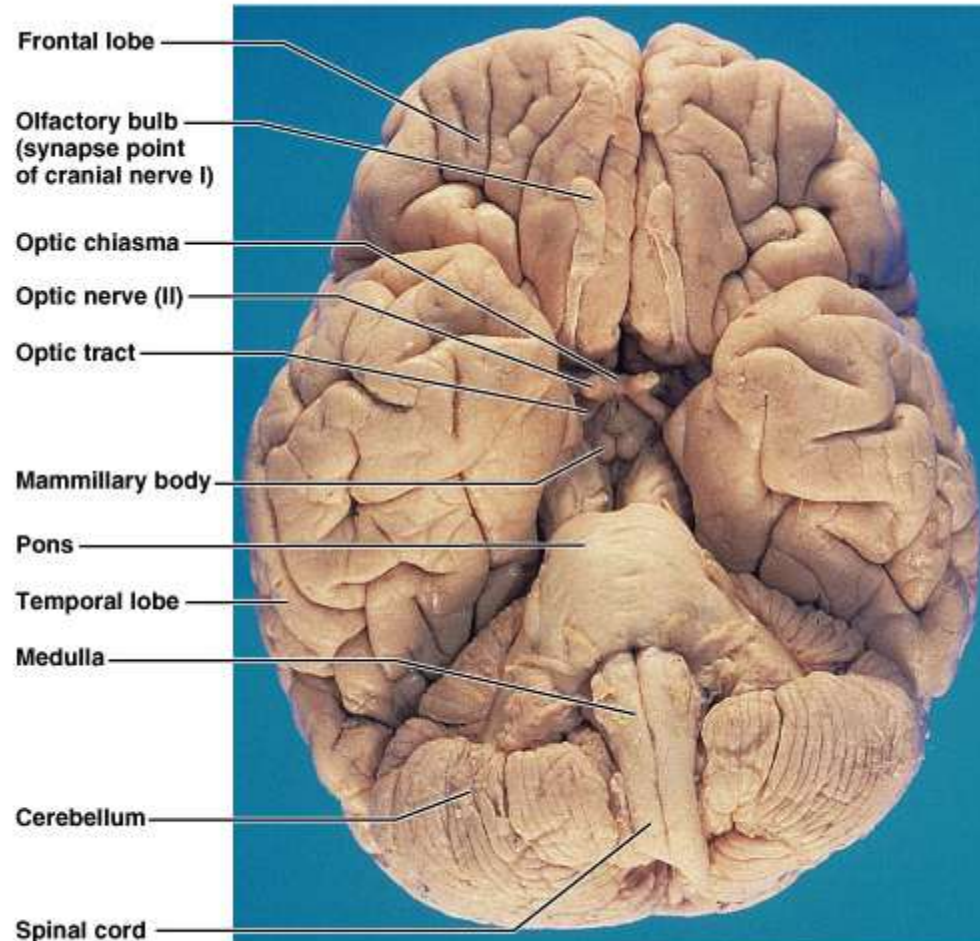
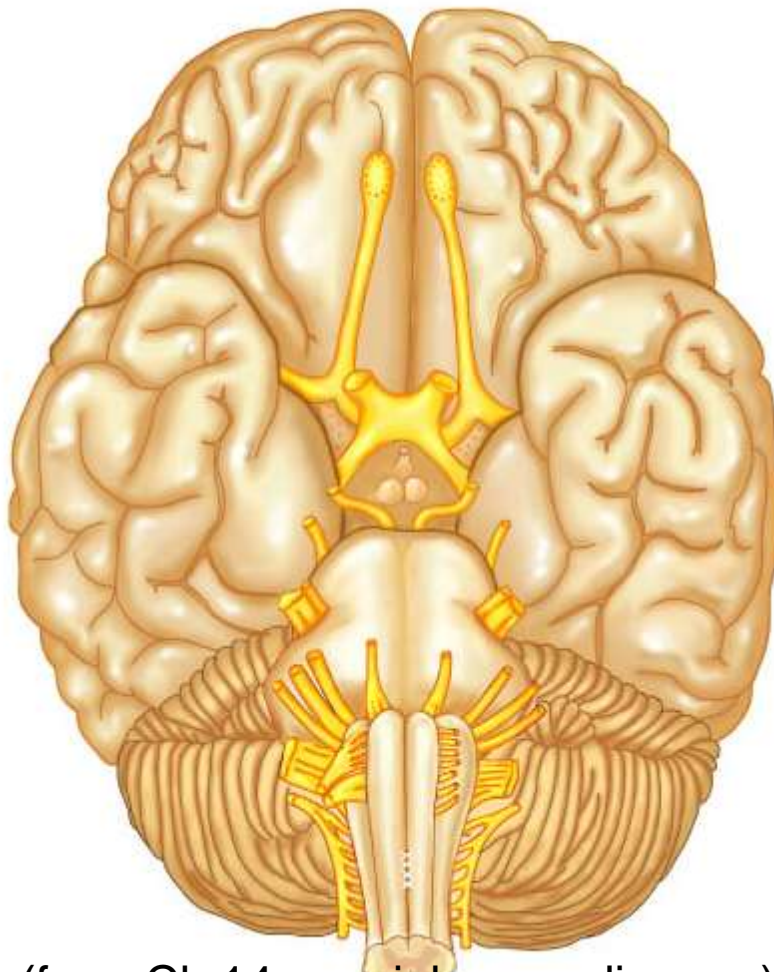
- Olfactory bulbs
- Olfactory tracts
- Optic nerves
- Optic chiasma (partial cross over)
- Optic tracts
- Mammillary bodies



(looking at brain from below)

Diencephalon – surface anatomy

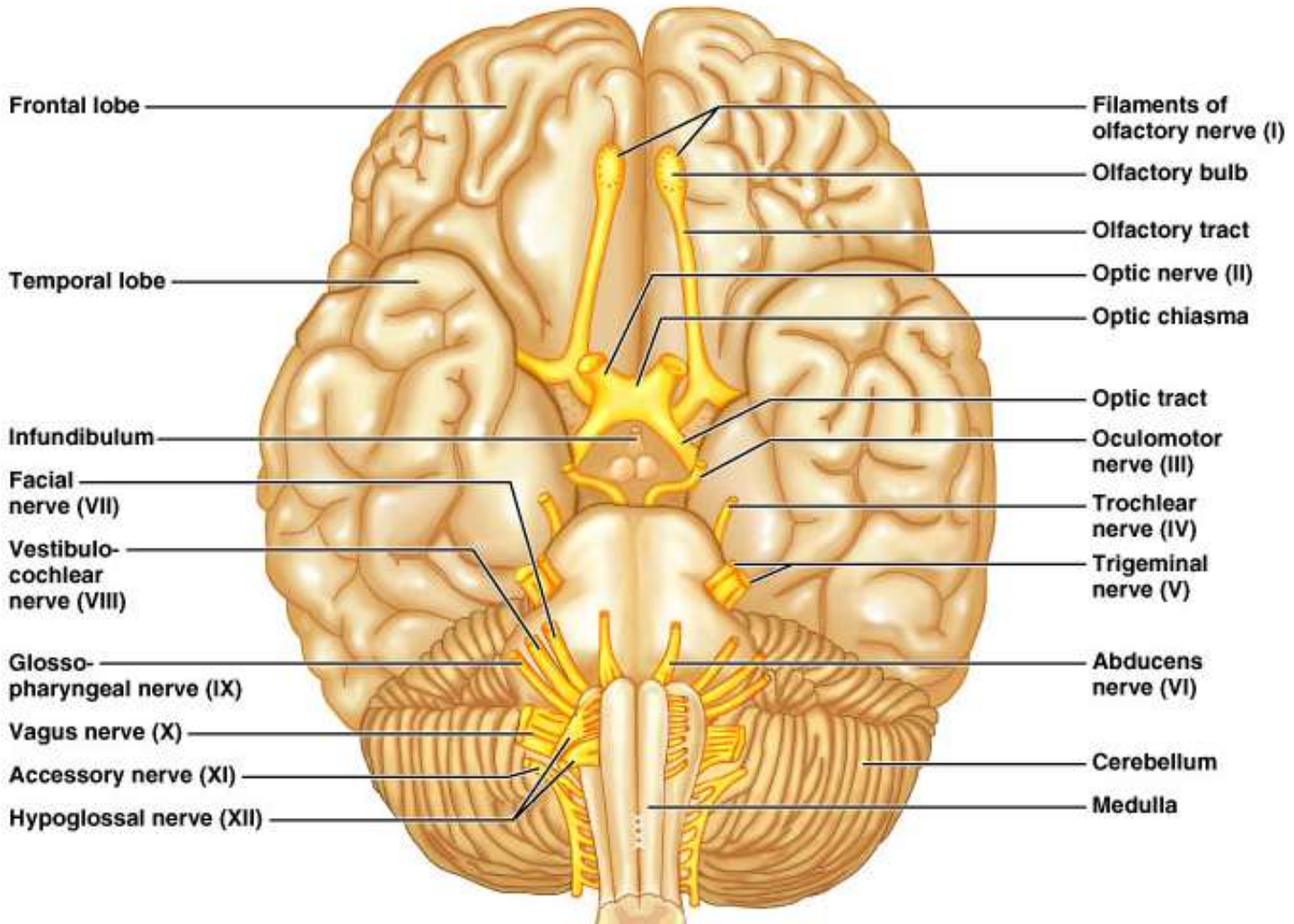
Hypothalamus is between optic chiasma to and including mamillary bodies



(from Ch 14: cranial nerve diagram)

Cranial Nerve names

Identify as many as you can when looking at model and sheep brain
(they will be more fully discussed in Chapter 14)



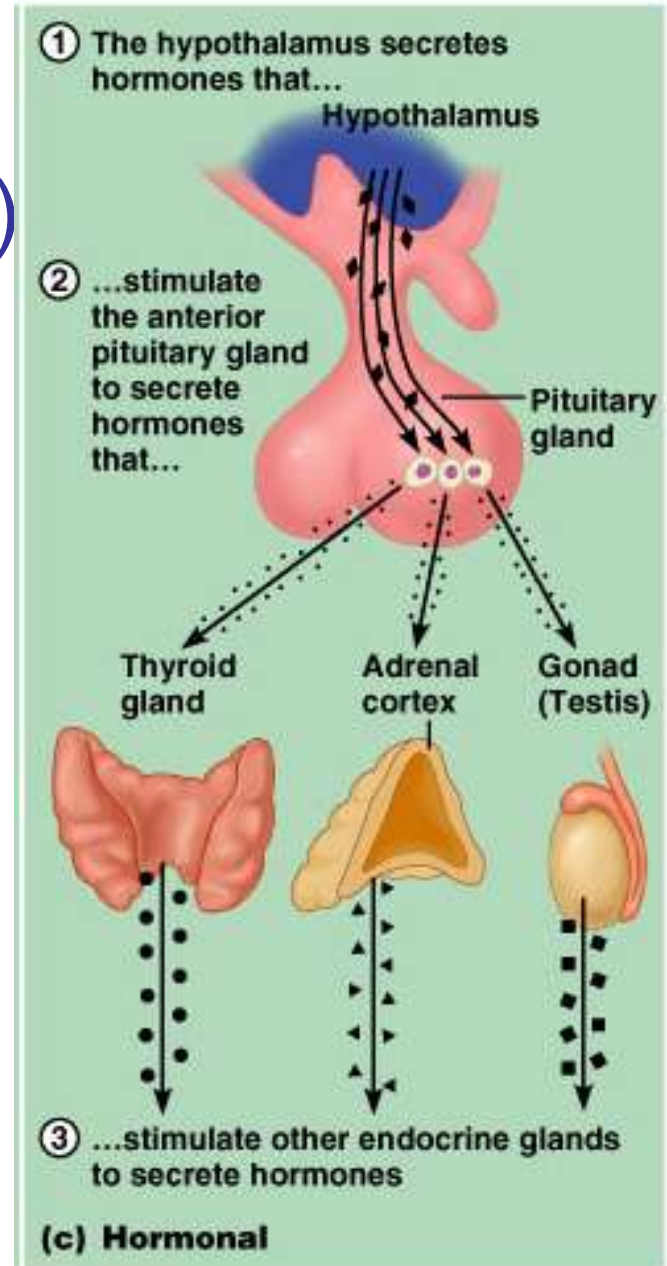
Hypothalamus

- “Below thalamus”
- Main visceral control center
 - Autonomic nervous system (peripheral motor neurons controlling smooth and cardiac muscle and gland secretions): heart rate, blood pressure, gastrointestinal tract, sweat and salivary glands, etc.
 - Emotional responses (pleasure, rage, sex drive, fear)
 - Body temp, hunger, thirst sensations
 - Some behaviors
 - Regulation of sleep-wake centers: circadian rhythm (receives info on light/dark cycles from optic nerve)
 - Control of endocrine system through pituitary gland
 - Involved, with other sites, in formation of memory

Hypothalamus

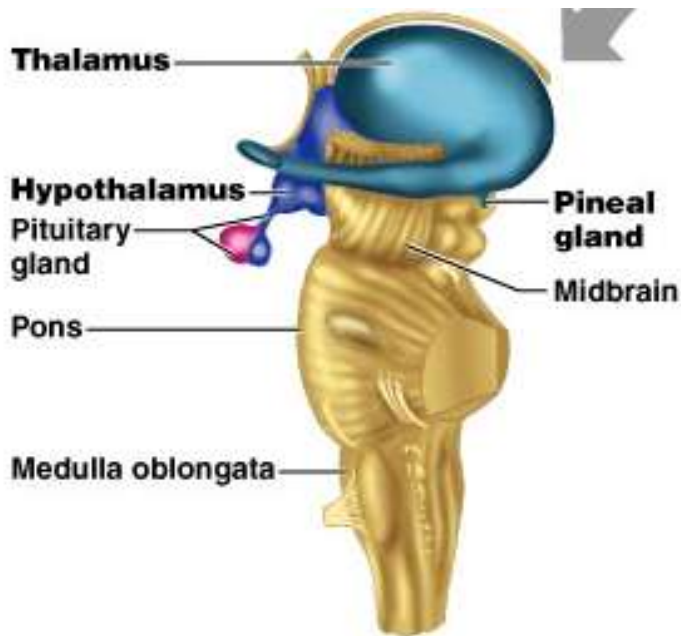
(one example of its functioning)

Control of
endocrine system
through pituitary
gland

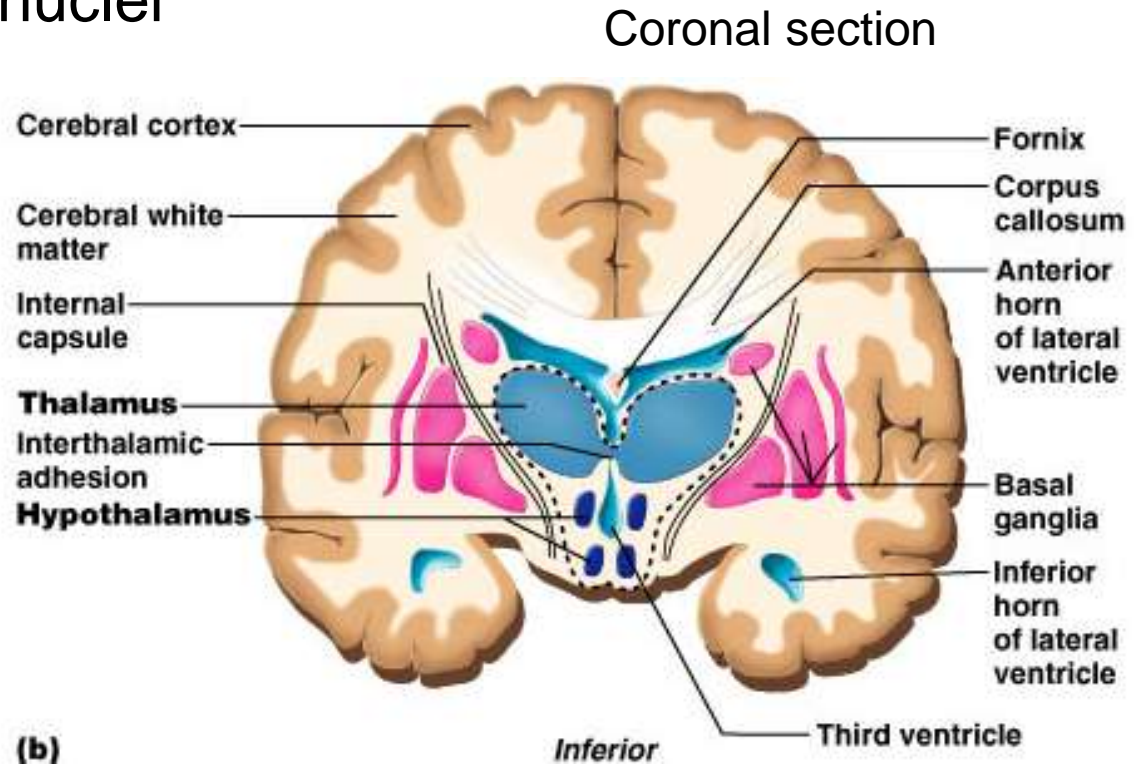


Epithalamus

- Third and most dorsal part of diencephalon
- Part of roof of 3rd ventricle
- Pineal gland or body (unpaired): produces melatonin signaling nighttime sleep
- Also a tiny group of nuclei



(a)

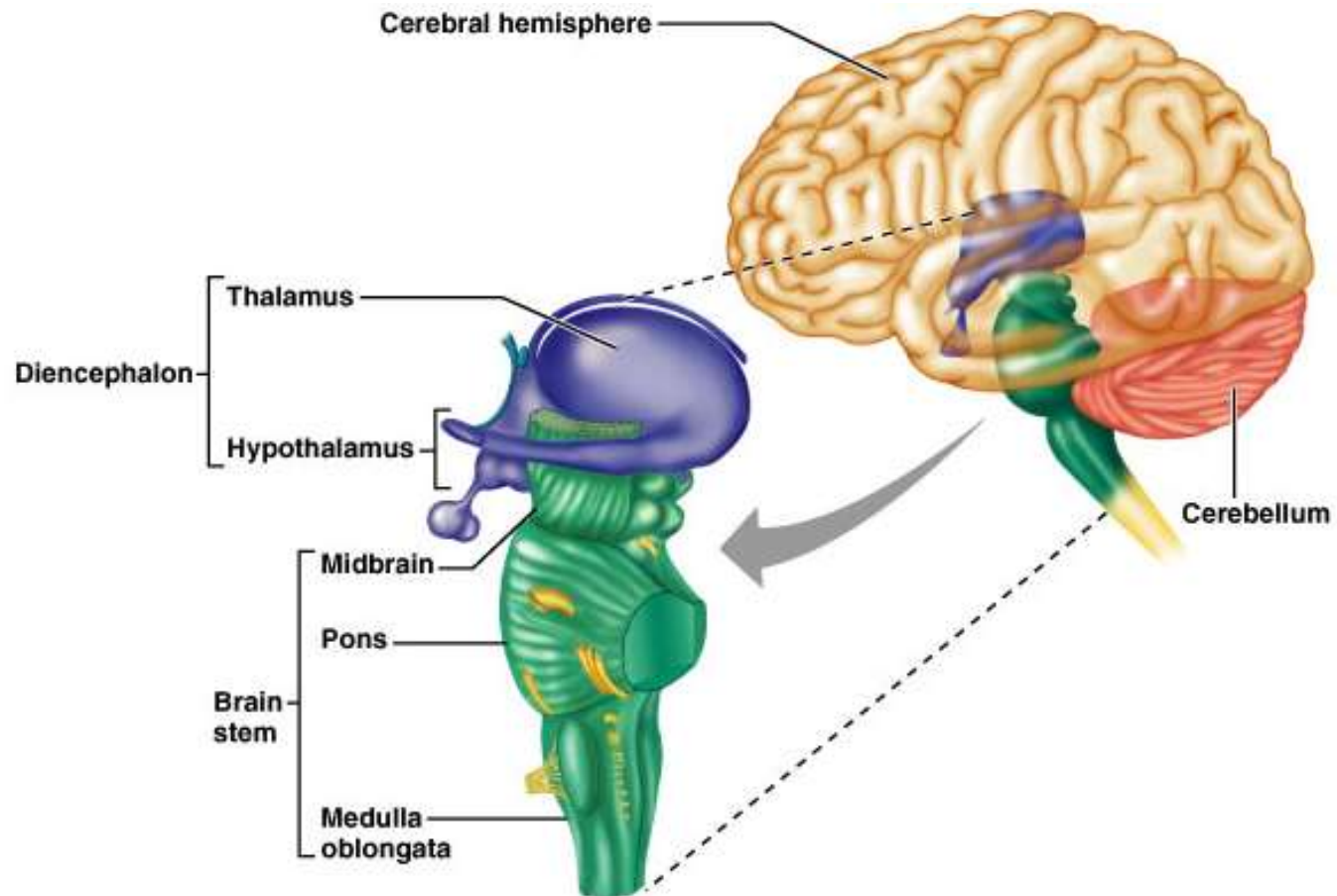


(b)

Brain Stem

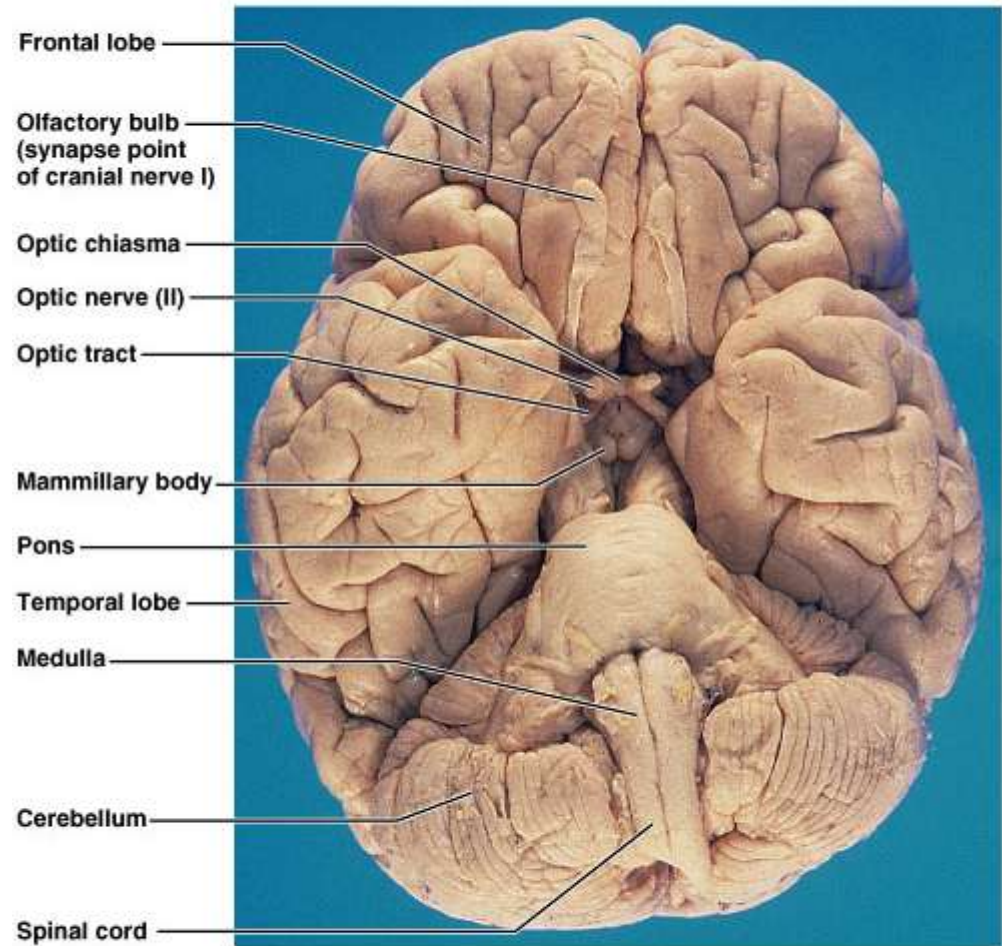
Rigidly programmed automatic behavior necessary for survival
Passageway for fiber tracts running between cerebrum and spinal cord
Heavily involved with innervation of face and head (10 of the 12 cranial nerves attach to it)

- Midbrain
- Pons
- Medulla oblongata

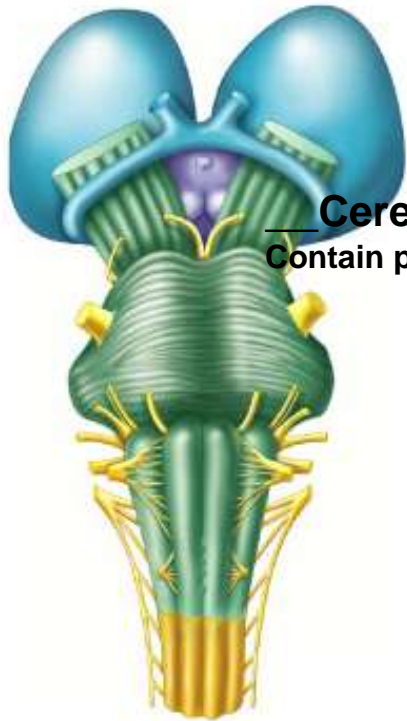

Brain stem

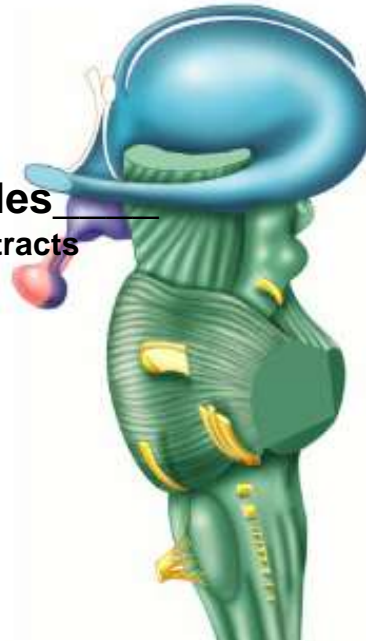- Midbrain
- Pons
- Medulla oblongata



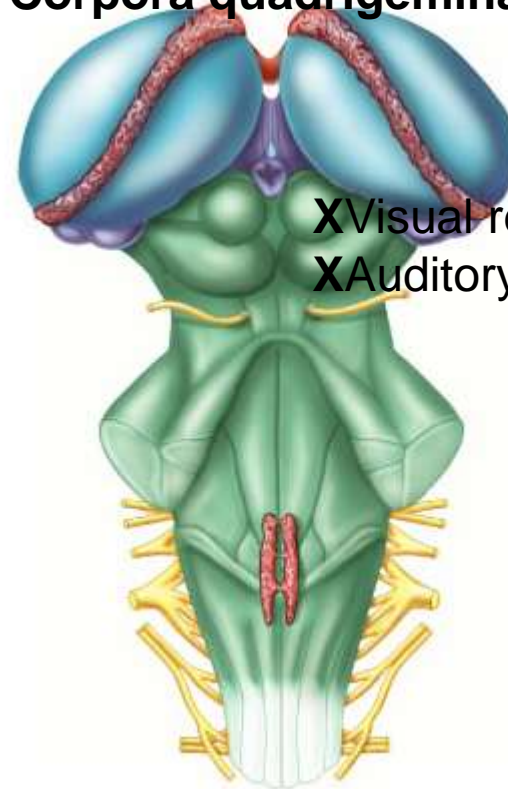Midbrain



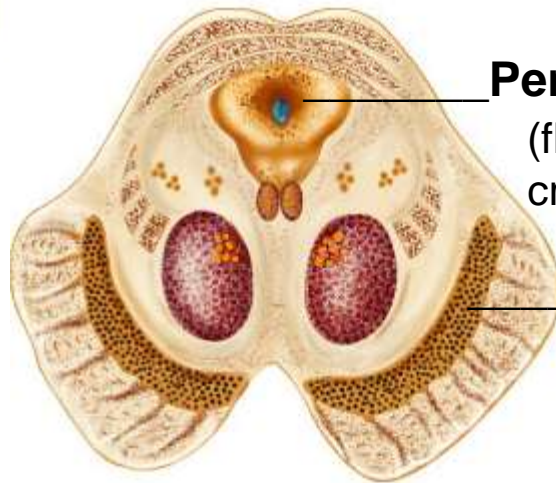
Cerebral peduncles
Contain pyramidal motor tracts



Corpora quadrigemina:



X Visual reflexes
X Auditory reflexes



Periaqueductal gray

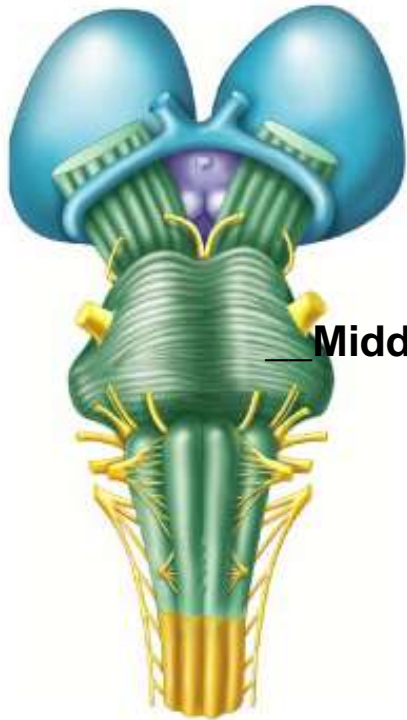
(flight/fright; nausea with visceral pain; some cranial nerve nuclei)

Substantia nigra

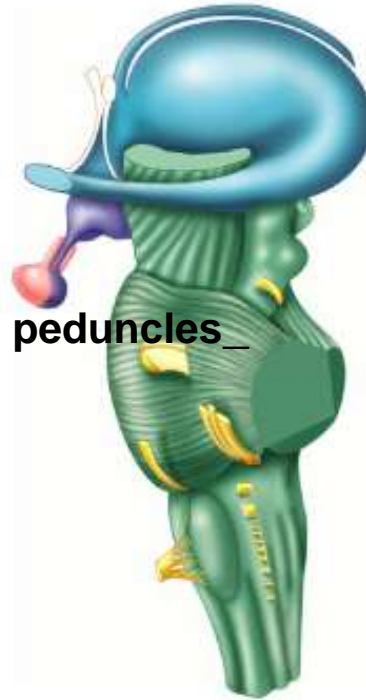(degeneration causes Parkinson's disease)

Pons

Also contains several CN and other nuclei

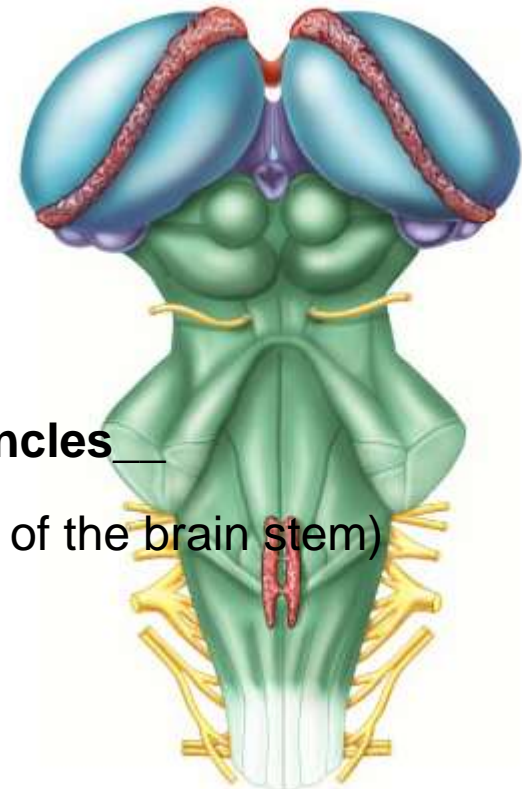


Middle cerebellar peduncles



3 cerebellar peduncles

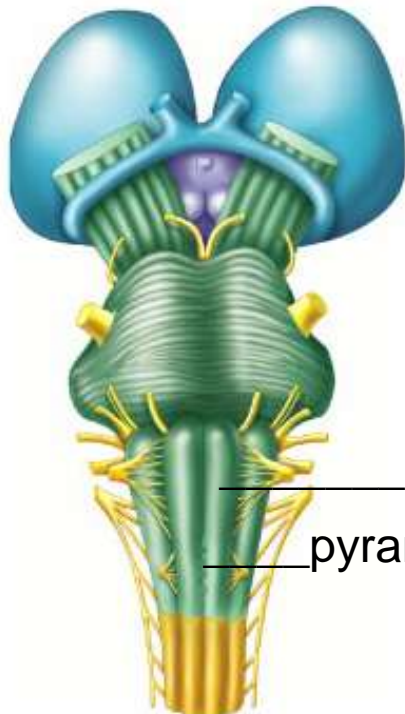
(one to each of the three parts of the brain stem)



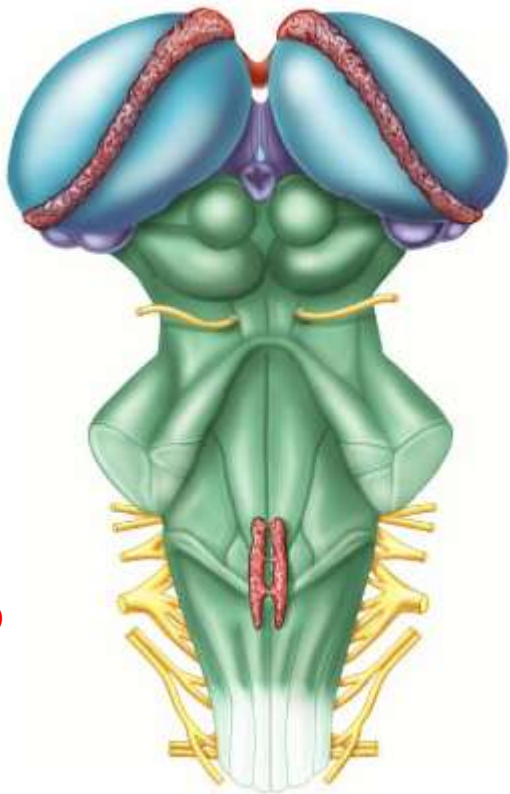
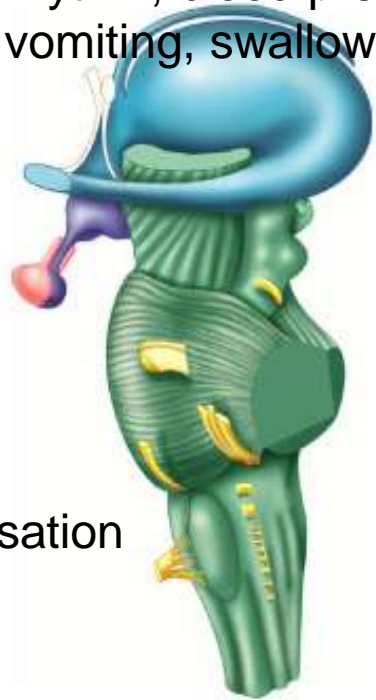Dorsal view

Medulla oblongata

Relays sensory info to cerebral cortex and cerebellum
Contains many CN and other nuclei
Autonomic centers controlling heart rate, respiratory rhythm, blood pressure; involuntary centers of vomiting, swallowing, etc.



Pyramids
pyramidal decussation

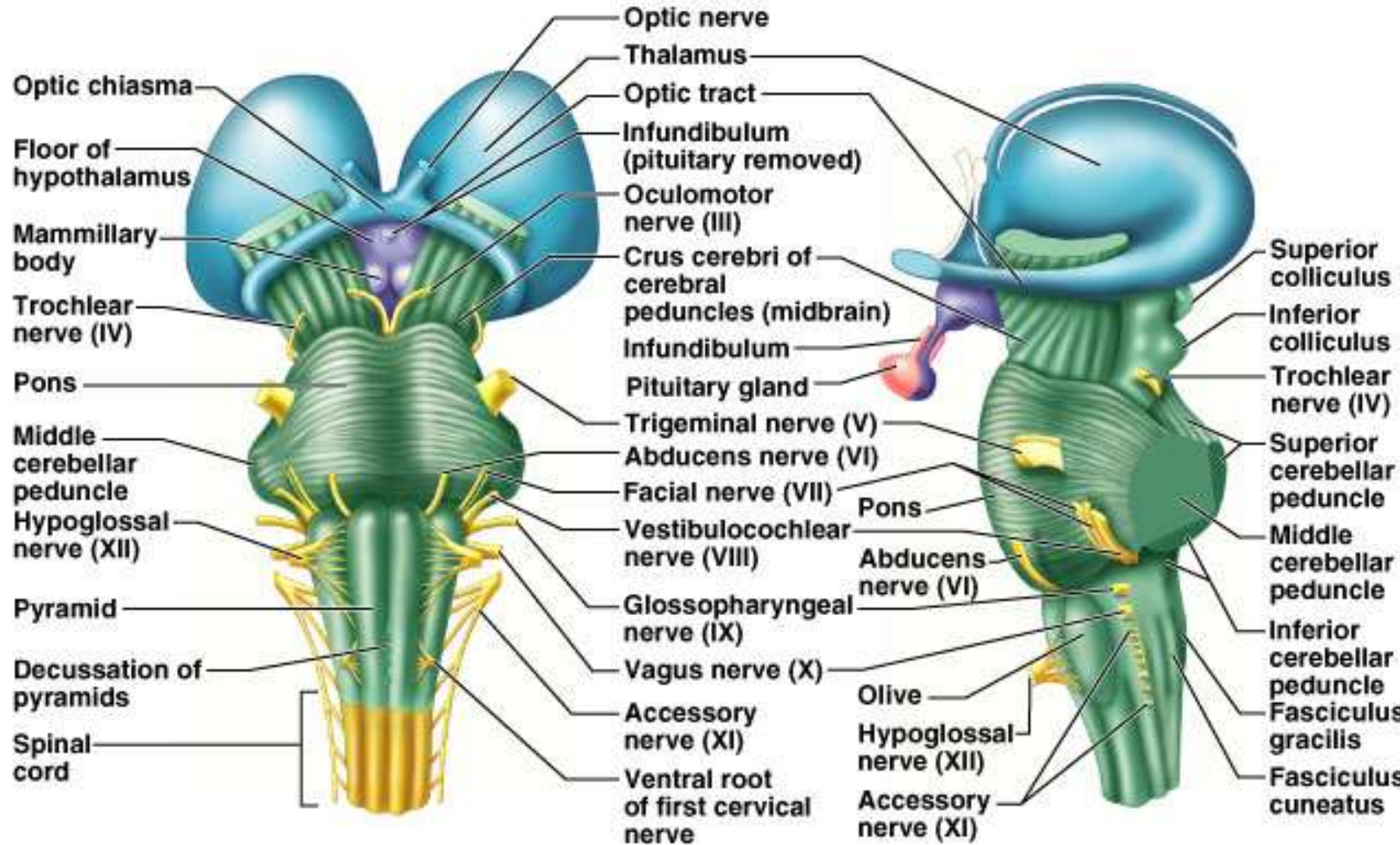


Dorsal view

“Pyramidal”=corticospinal tracts; these are motor tracts which cross over in the decussation. They are named pyramids because they supposedly look like them, and also they originate from “pyramidal” neurons in the motor cortex. The tracts have the name of origin 1st, therefore “corticospinal” tells you they go from the cortex (“cortico-”) to the spinal cord (“-spinal”)

see later slides

With all the labels....

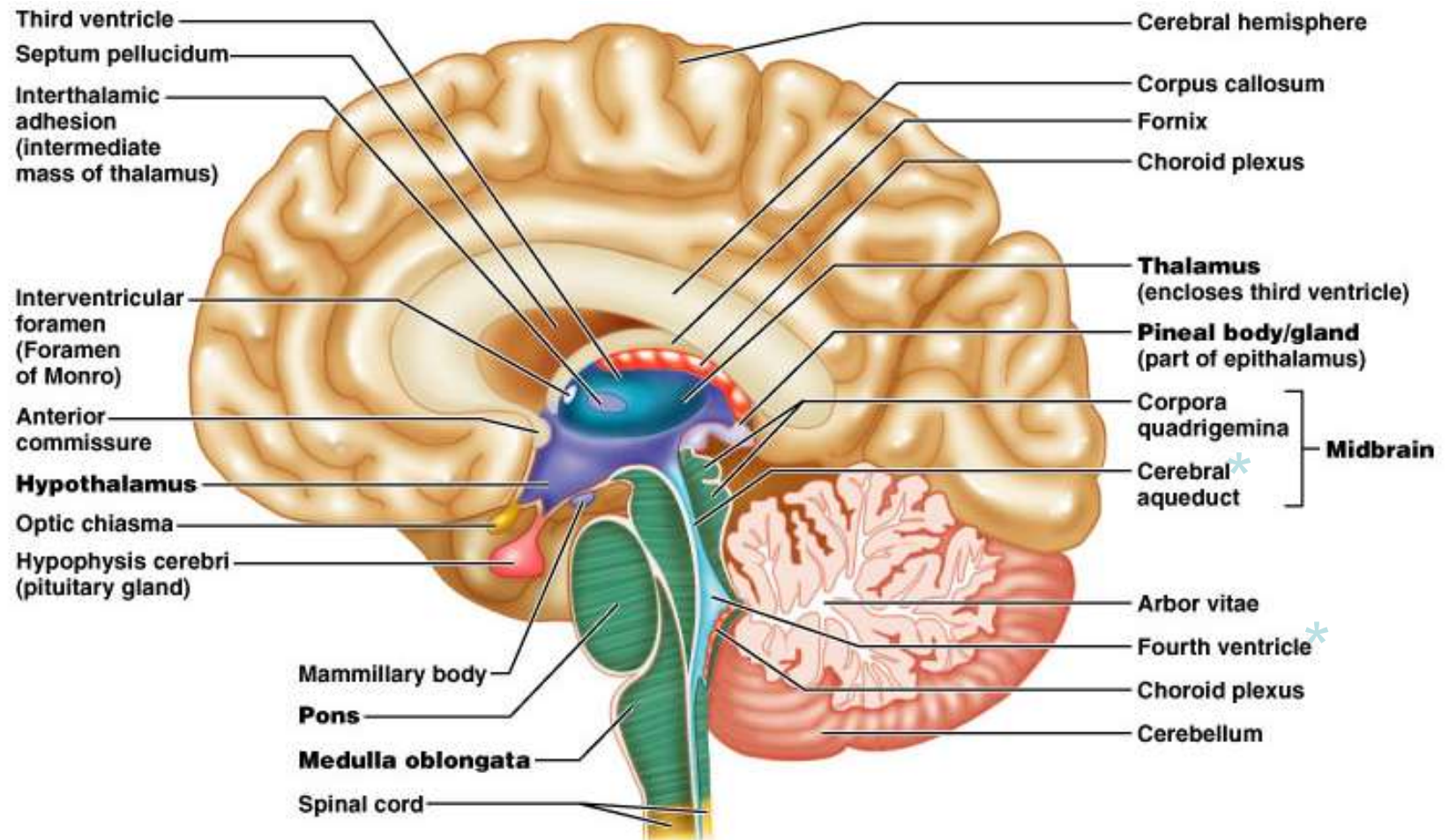


(a) Ventral view

(b) Lateral view

Brain Stem in mid-sagittal plane

Note cerebral aqueduct and fourth ventricle*



Cerebellum

Two major hemispheres: three lobes each

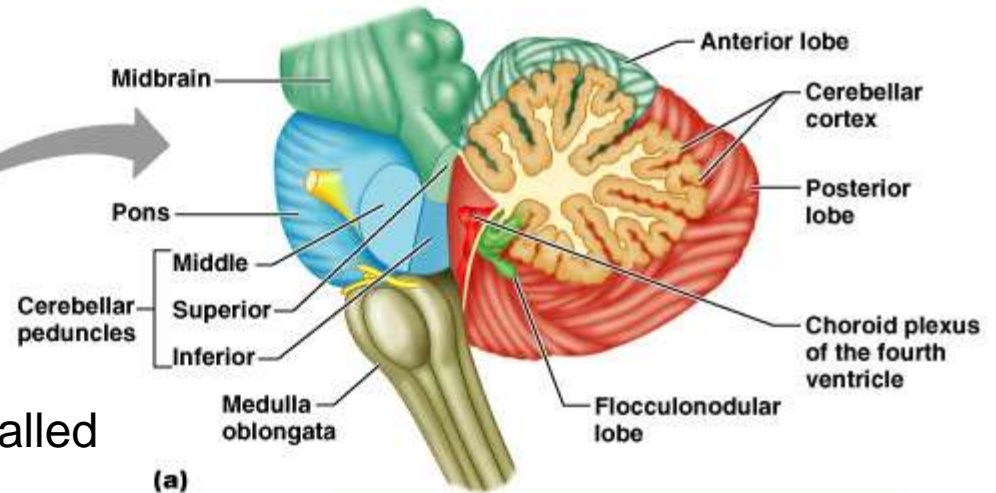
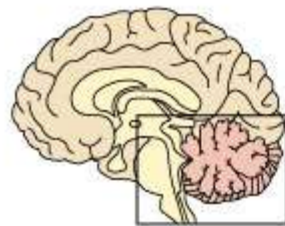
Anterior

Posterior

Flocculonodular

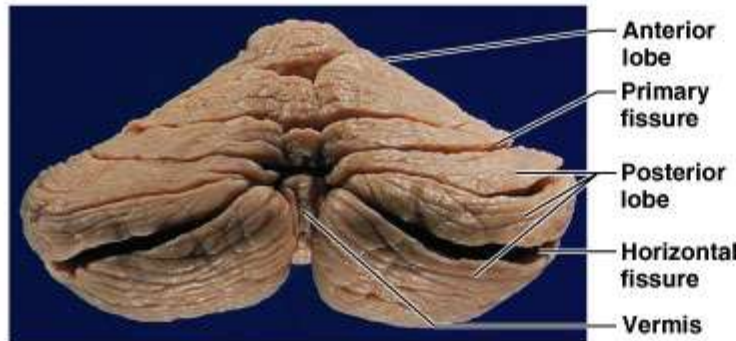
Vermis: midline lobe connecting hemispheres

Separated from brain stem by 4th ventricle

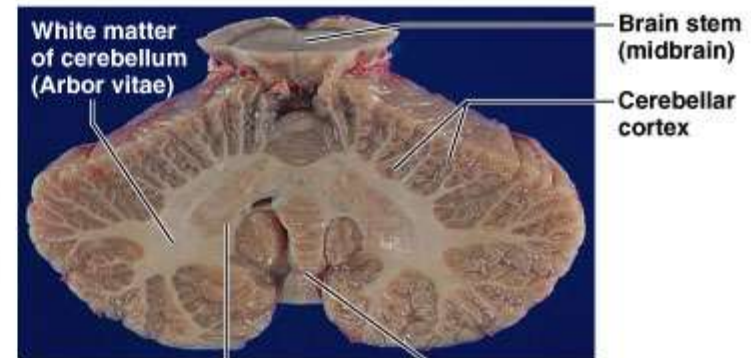


Outer cortex of gray

Inner branching white matter, called "arbor vitae"



(b) Posterior view



(c) Frontal section

Functions of cerebellum

- Smooths, coordinates & fine tunes bodily movements
- Helps maintain body posture
- Helps maintain equilibrium
- How?
 - Gets info from cerebrum re: movements being planned
 - Gets info from inner ear re: equilibrium
 - Gets info from proprioceptors (sensory receptors informing where the parts of the body actually are)
 - Using feedback, adjustments are made
- Also some role in cognition

- Damage: ataxia, incoordination, wide-based gait, overshooting, proprioception problems

Functional brain systems

(as opposed to anatomical ones)

Networks of distant neurons that function together

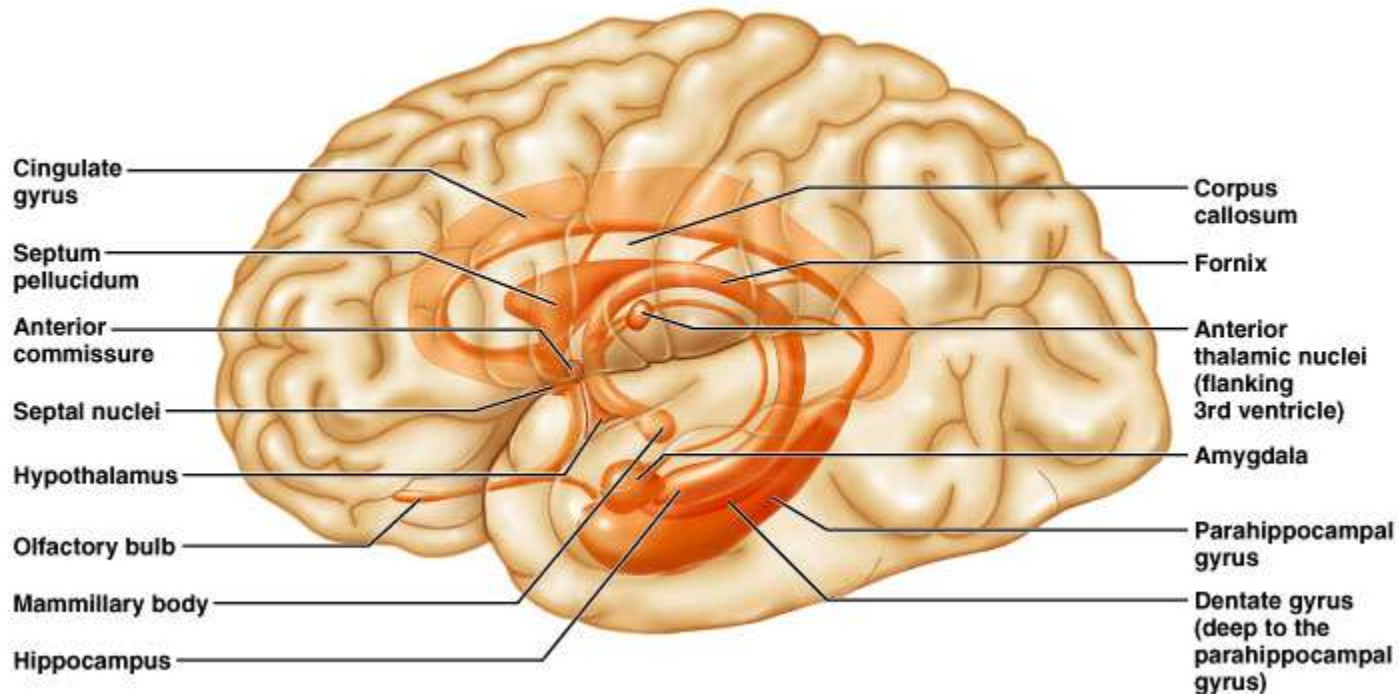
Limbic system

Reticular formation

Limbic system

(not a discrete structure - includes many brain areas)

- Most important parts:
 - Hippocampus
 - Amygdala
 - Cingulate gyrus
 - Orbitofrontal cortex (not labeled; is behind eyes - part of the prefrontal cortex but connects closely)



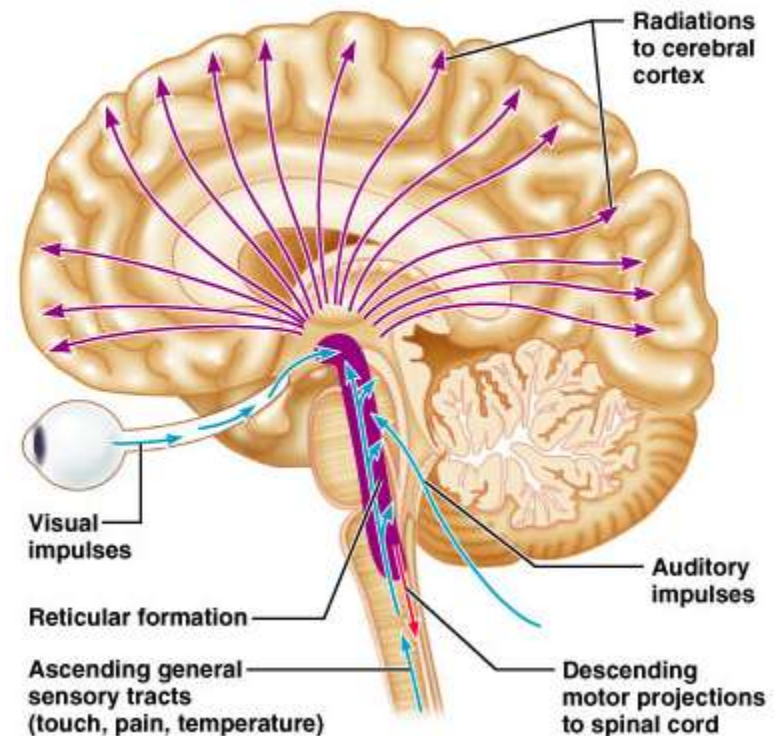
Limbic system continued

- Called the “emotional” brain
- Is essential for flexible, stable, adaptive functioning
- Links different areas so integration can occur
 - Integration: separate things are brought together as a whole
 - Processes emotions and allocates attentional resources
- Necessary for emotional balance, adaptation to environmental demands (including fearful situations, etc.), for creating meaningful connections with others (e.g. ability to interpret facial expressions and respond appropriately), and more...

Reticular formation

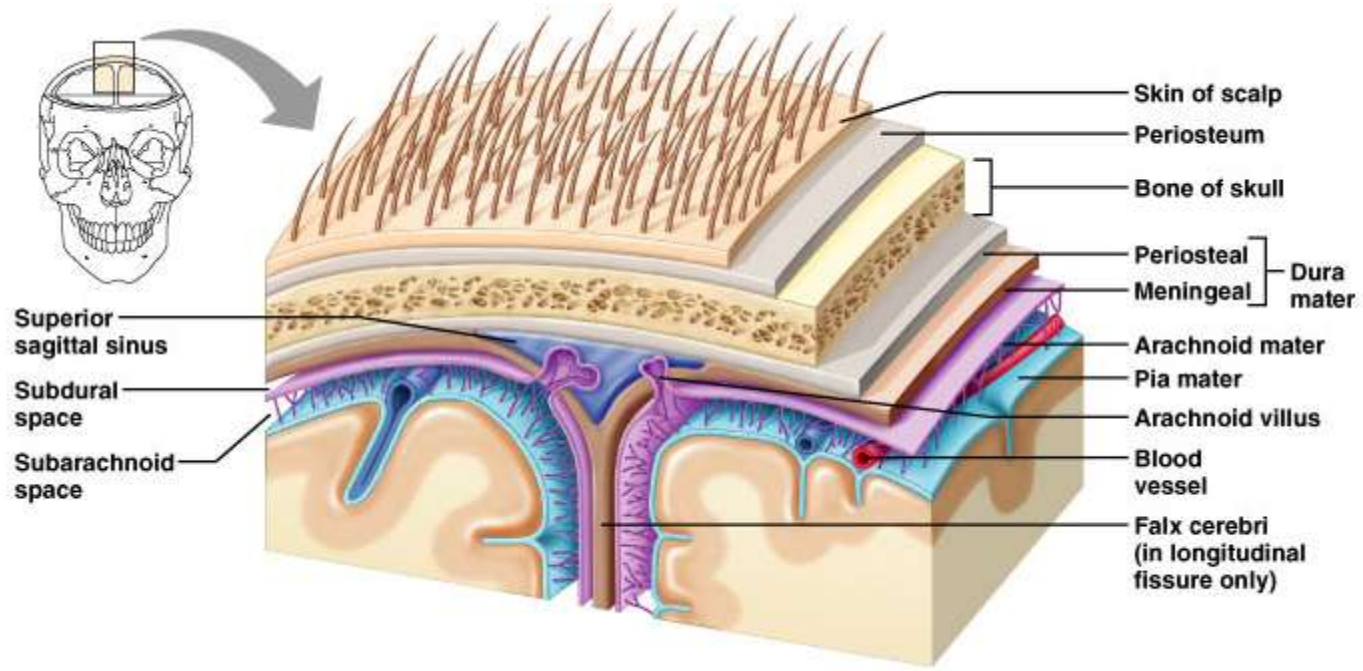
Runs through central core of medulla, pons and midbrain

- Reticular activating system (RAS): keeps the cerebral cortex alert and conscious
- Some motor control



Brain protection

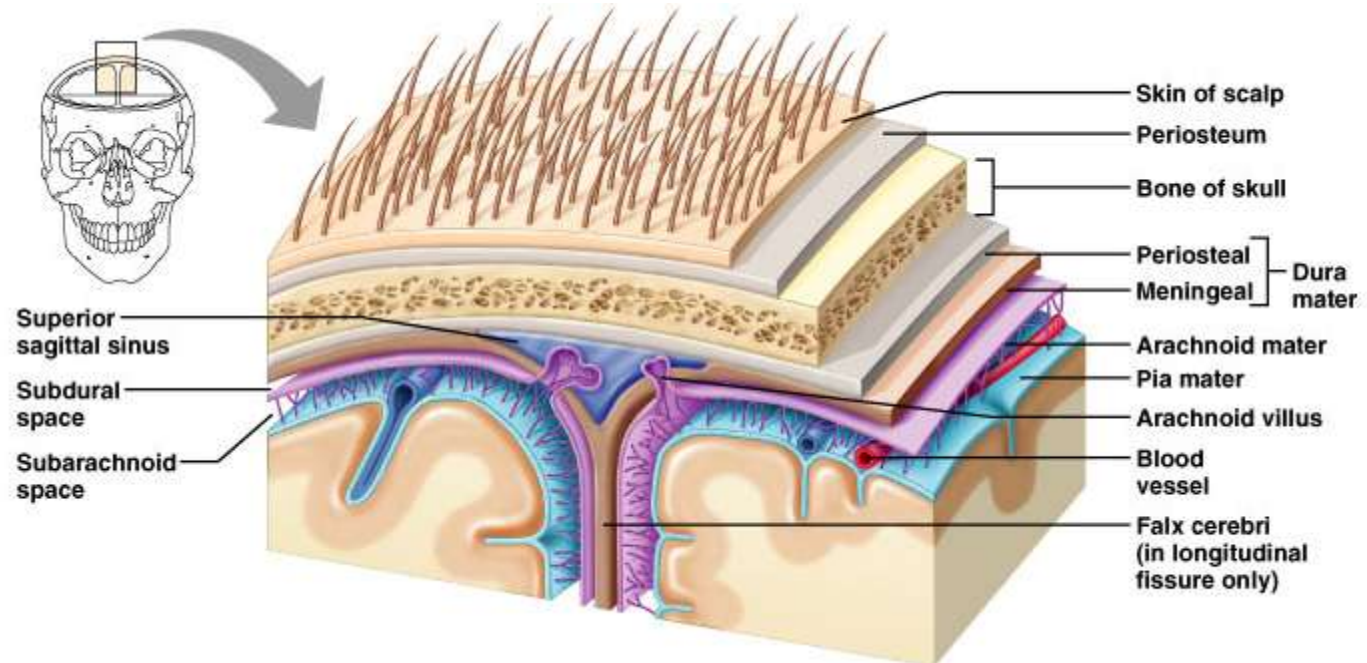
1. Meninges
2. Cerebrospinal fluid
3. Blood brain barrier



Meninges

- 1. *Dura mater*:** 2 layers of fibrous connective tissue, fused except for dural sinuses
 - Periosteal layer attached to bone
 - Meningeal layer - proper brain covering
- 2. *Arachnoid mater***
- 3. *Pia mater***

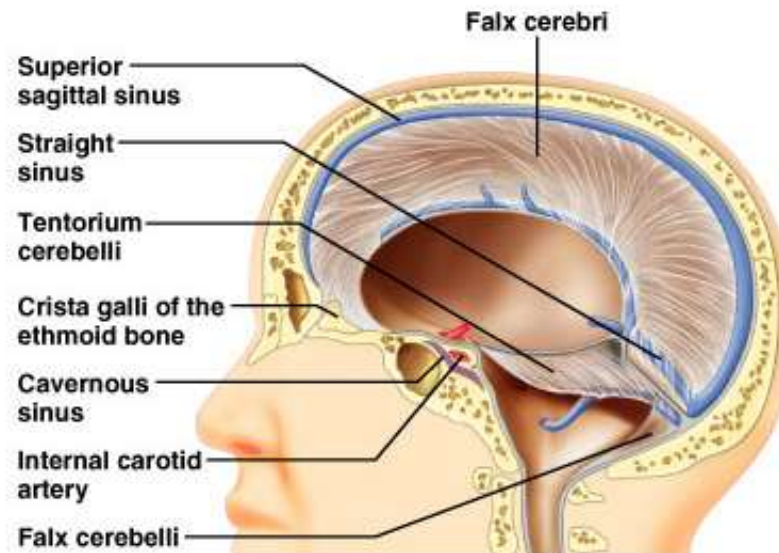
Note superior sagittal sinus

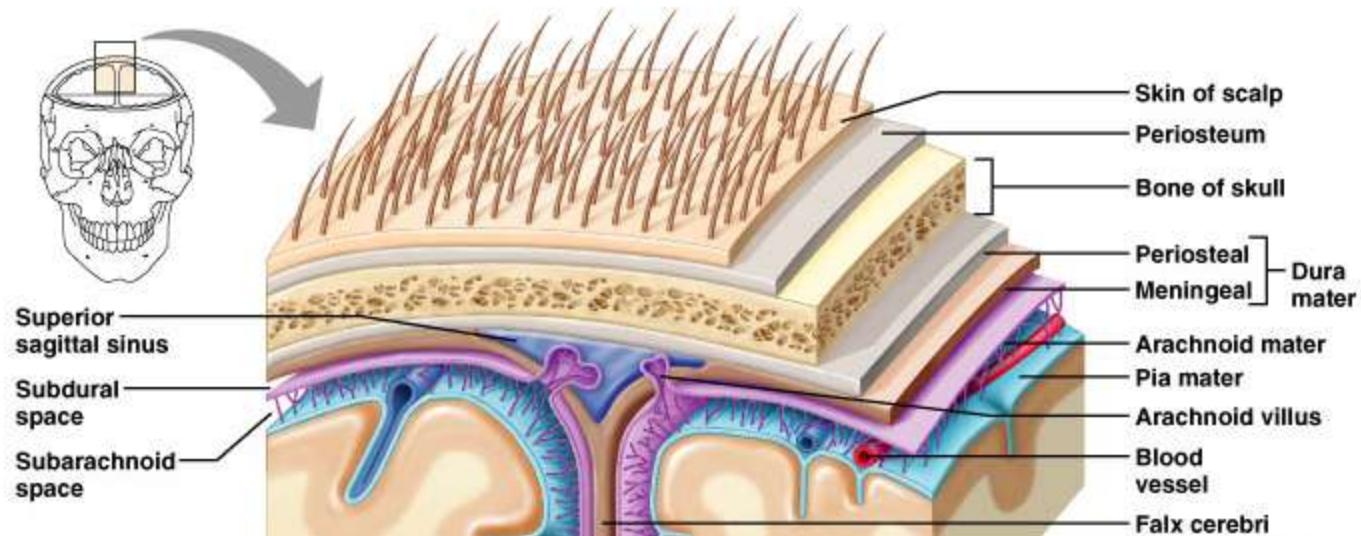


Dura mater - dural partitions

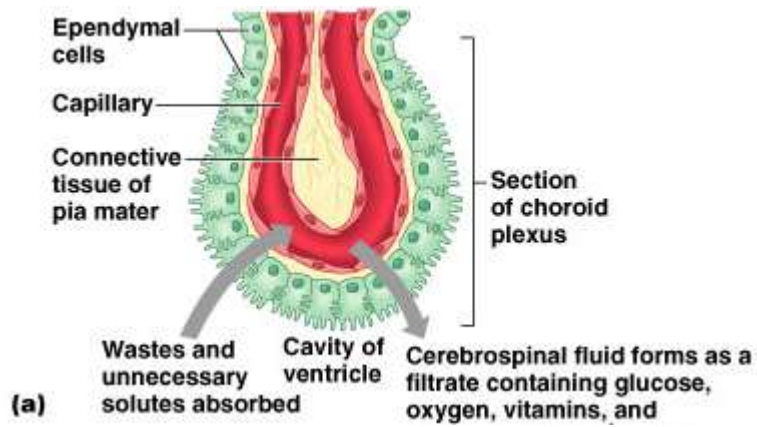
Subdivide cranial cavity & limit movement of brain

- Falx cerebri
 - In longitudinal fissure; attaches to crista galli of ethmoid bone
- Falx cerebelli
 - Runs vertically along vermis of cerebellum
- Tentorium cerebelli
 - Sheet in transverse fissure between cerebrum & cerebellum





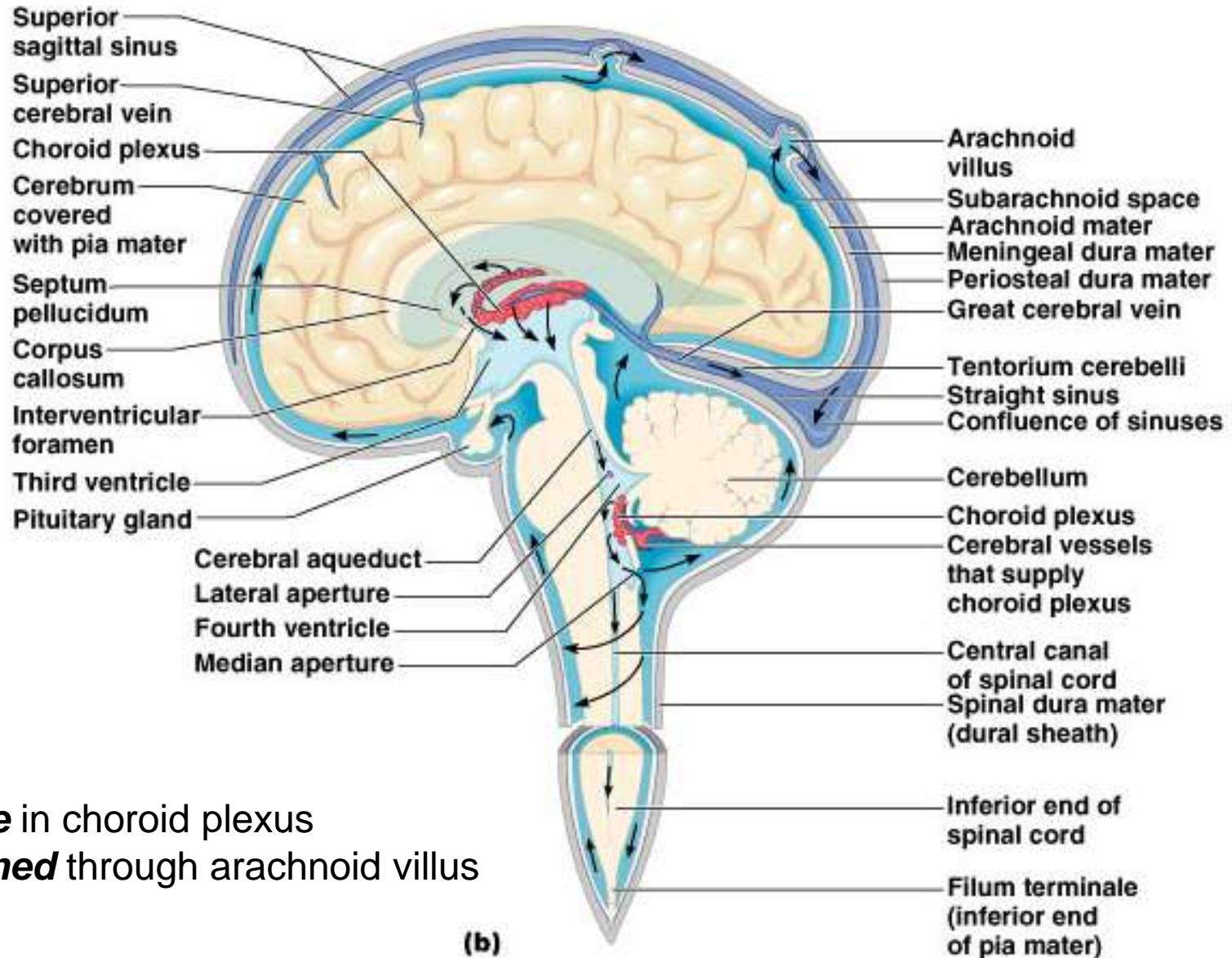
- Arachnoid mater
 - Between dura and arachnoid: **subdural space**
 - Dura and arachnoid cover brain loosely
 - Deep to arachnoid is **subarachnoid space**
 - Filled with CSF
 - Lots of vessels run through (susceptible to tearing)
 - Superiorly, forms arachnoid villi: CSF valves
 - Allow draining into dural blood sinuses
- Pia mater
 - Delicate, clings to brain following convolutions



Cerebrospinal Fluid CSF

- Made in choroid plexuses (roofs of ventricles)
 - Filtration of plasma from capillaries through ependymal cells (electrolytes, glucose)
- 500 ml/d; total volume 100-160 ml (1/2 c)
- Cushions and nourishes brain
- Assayed in diagnosing meningitis, bleeds, MS
- Hydrocephalus: excessive accumulation

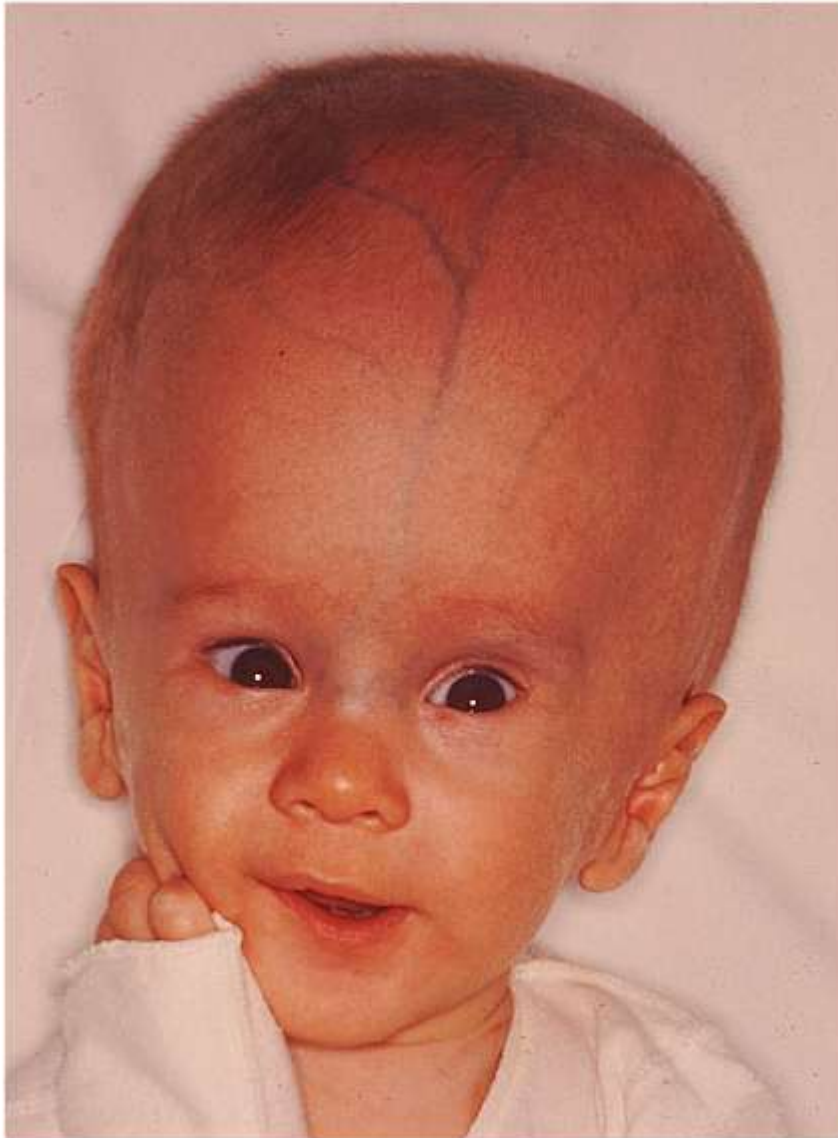
CSF circulation: through ventricles, median and lateral apertures, subarachnoid space, arachnoid villi, and into the blood of the superior sagittal sinus



CSF:

- **Made** in choroid plexus
- **Drained** through arachnoid villus

(b)



Hydrocephalus

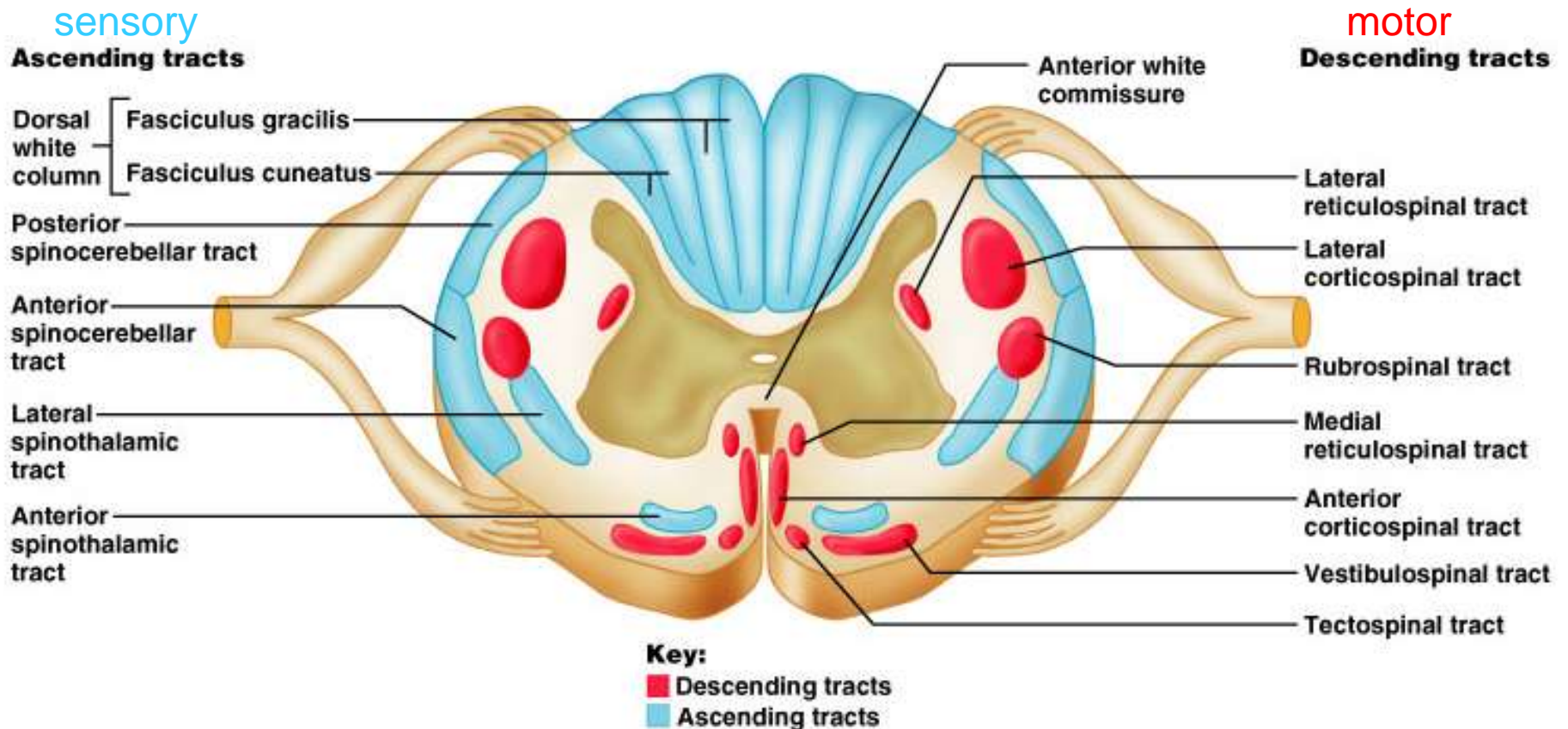
Blood-Brain Barrier

- Tight junctions between endothelial cells of brain capillaries, instead of the usual permeability
- Highly selective transport mechanisms
- Allows nutrients, O₂, CO₂
- ***Not*** a barrier against uncharged and lipid soluble molecules; allows alcohol, nicotine, and some drugs including anesthetics

White matter of the spinal cord

- **Ascending** pathways: **sensory** information by multi-neuron chains from body up to more rostral regions of CNS
 - Dorsal column
 - Spinothalamic tracts
 - Spinocerebellar tracts
- **Descending** pathways: **motor** instructions from brain to more caudal regions of the CNS
 - Pyramidal (corticospinal) most important to know
 - All others (“extrapyramidal”)
- Commissural fibers: crossing from one side of cord to the other
- Most pathways cross (or decussate) at some point
- Most synapse two or three times along the way, e.g. in brain stem, thalamus or other

Major fiber tracts in white matter of spinal cord



Damage: to motor areas – paralysis
to sensory areas - paresthesias

Major **ascending** pathways for the somatic senses

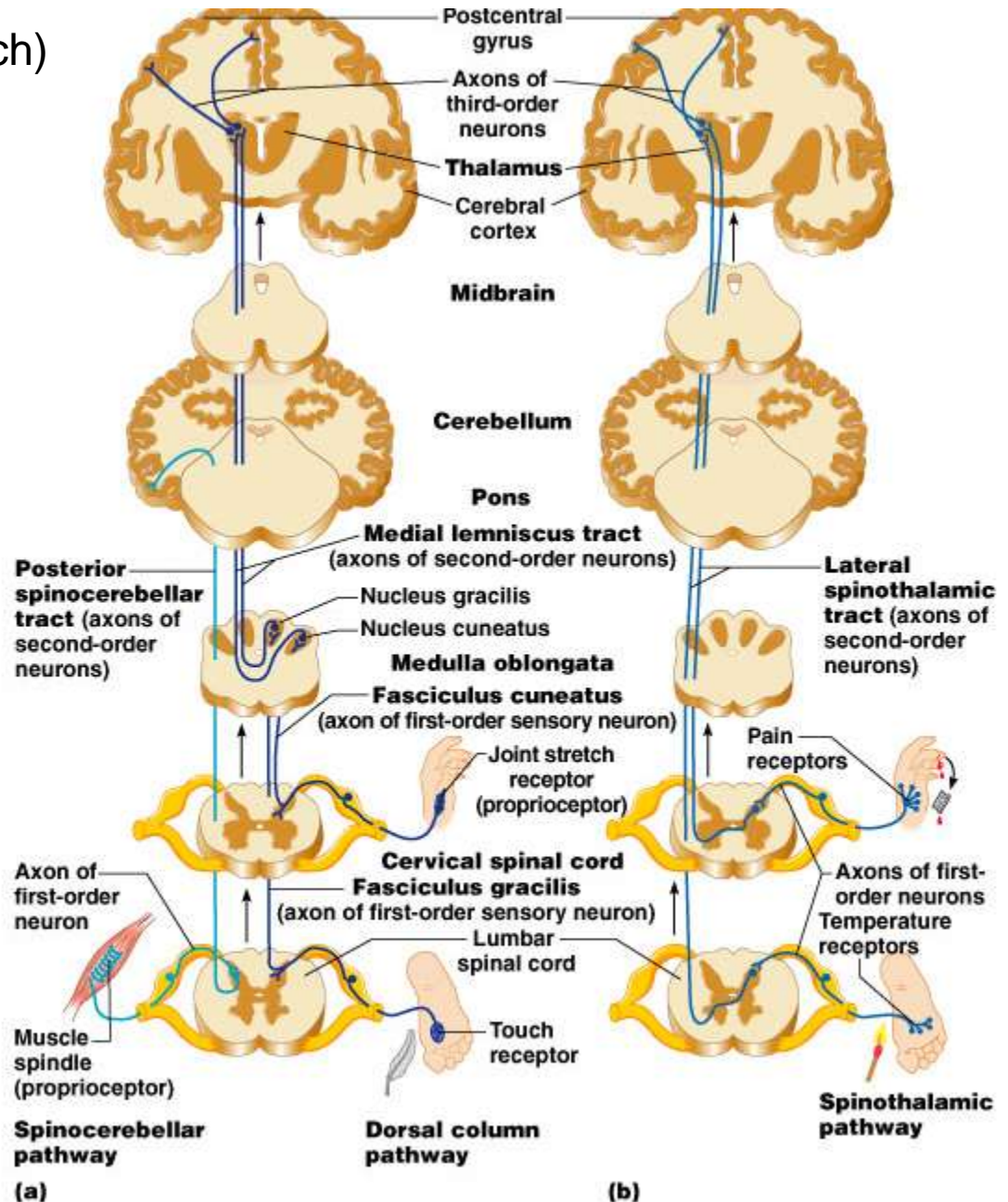
(thousands of nerve fibers in each)

Spinocerebellar:

proprioception from skeletal muscles to cerebellum of same side (don't cross)

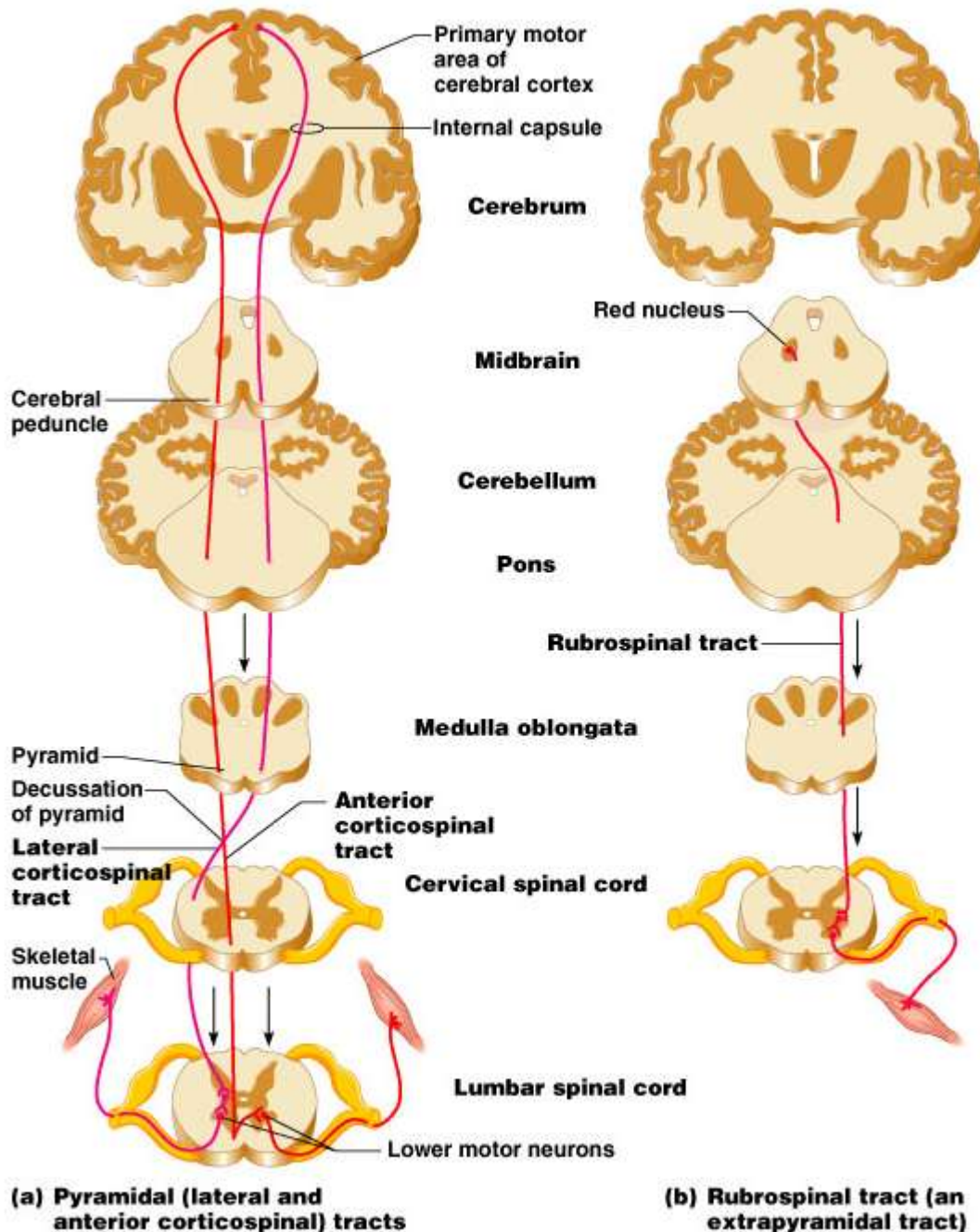
Dorsal column: discriminative touch sensation through thalamus to somatosensory cortex (cross in medulla)

Spinothalamic: carries nondiscriminate sensations (pain, temp, pressure) through the thalamus to the primary somatosensory cortex (cross in spinal cord before ascending)



Some Descending Pathways

Synapse with ventral (anterior) horn interneurons



Pyramidal tracts:

Lateral corticospinal – cross in pyramids of medulla; voluntary motor to limb muscles

Ventral (anterior) corticospinal – cross at spinal cord; voluntary to axial muscles

“Extrapyramidal” tracts: one example

- Check out: Medical gross anatomy atlas images (good teaching pics):

http://anatomy.med.umich.edu/atlas/atlas_index.html

(can access from Paul Wissman's site also:

- anatomy and physiology
- brain and spinal cord
- brain pics at U. Mich)

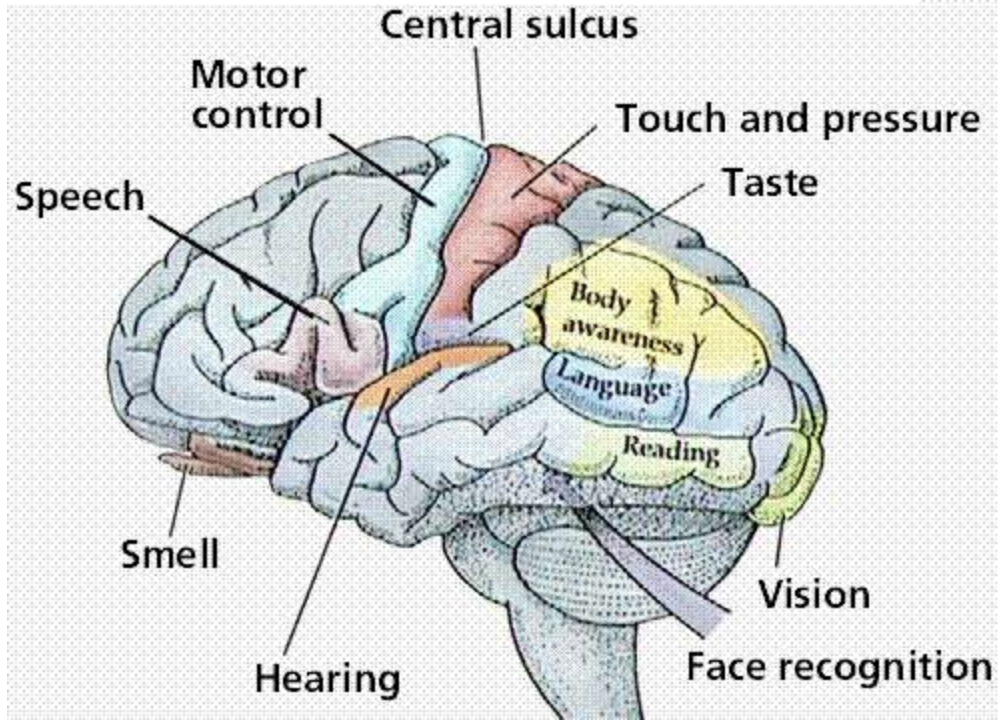
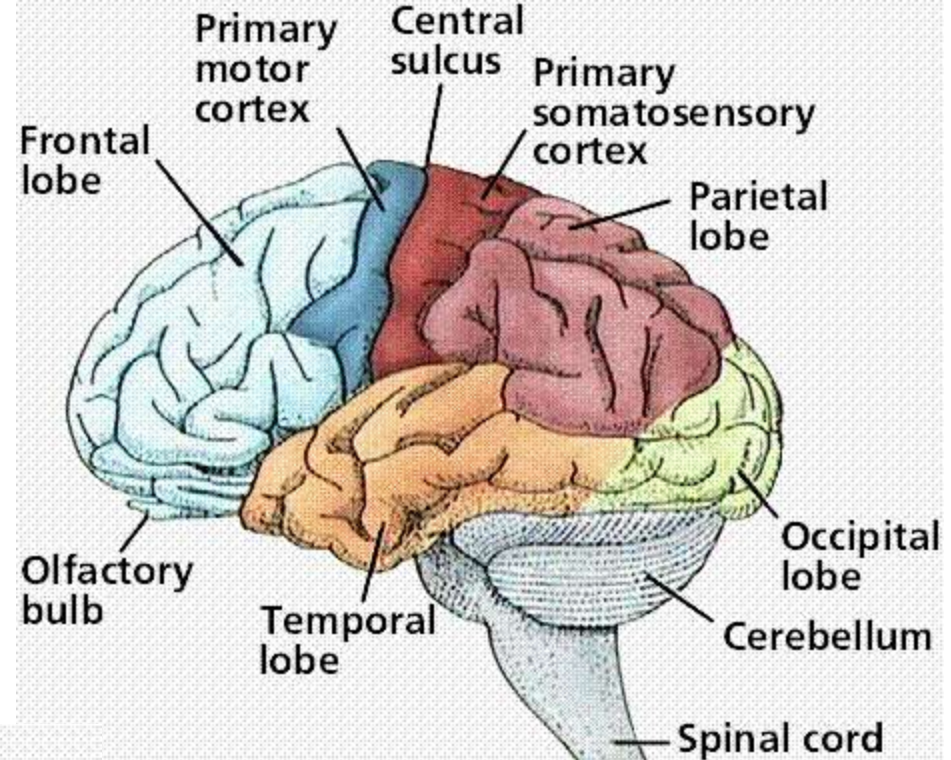
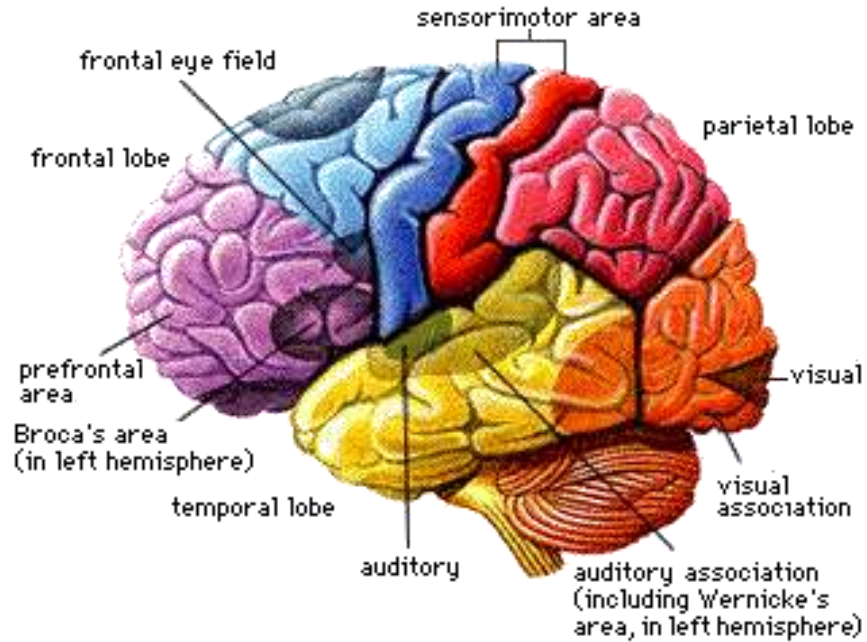
- Really good site for photos of human brain dissections:

<http://library.med.utah.edu/WebPath/HISTHTML/NEURANAT/NEURANCA.html>

Hints & additional pics

- Unless your prints of the slides are very large and clear, look at the pictures from the book on your computer screen or in the book itself so you can read all the labels
- Anything in bold, italicized or repeated should be learned
- Remembering the terminology from the quiz will help you figure things out
- Anterior horn cells = ventral motor neurons
- Forget funiculi; know dorsal column (spinal cord)

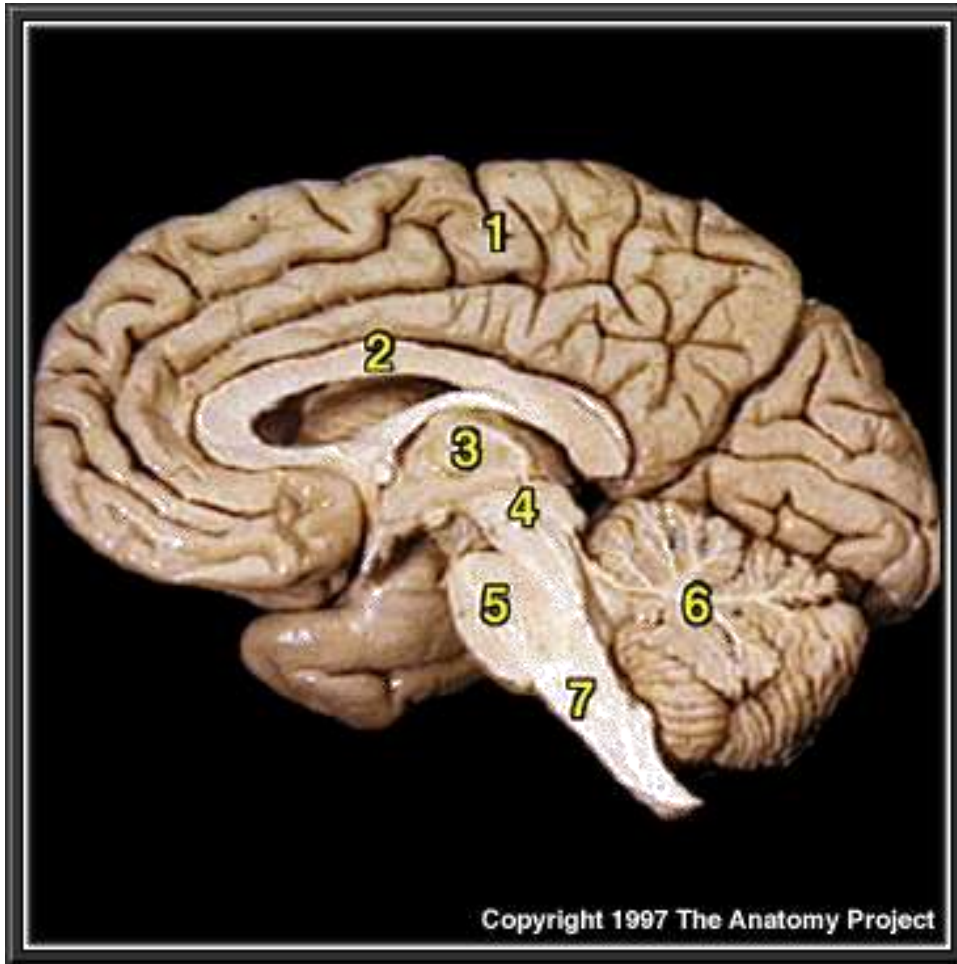
- Know the names of the ventricles and which ones connect to which, in order
- You don't need to know the #s of the Brodman areas
- You do need to know where are the: primary somatosensory, primary motor, broca's speech, visual cortex, the lobes of the brain, main sulci and fissures, precentral and postcentral gyri and which go with which of motor and sensory, etc
- For the most part, the medical info is FYI



From this site, which also has text explanations:

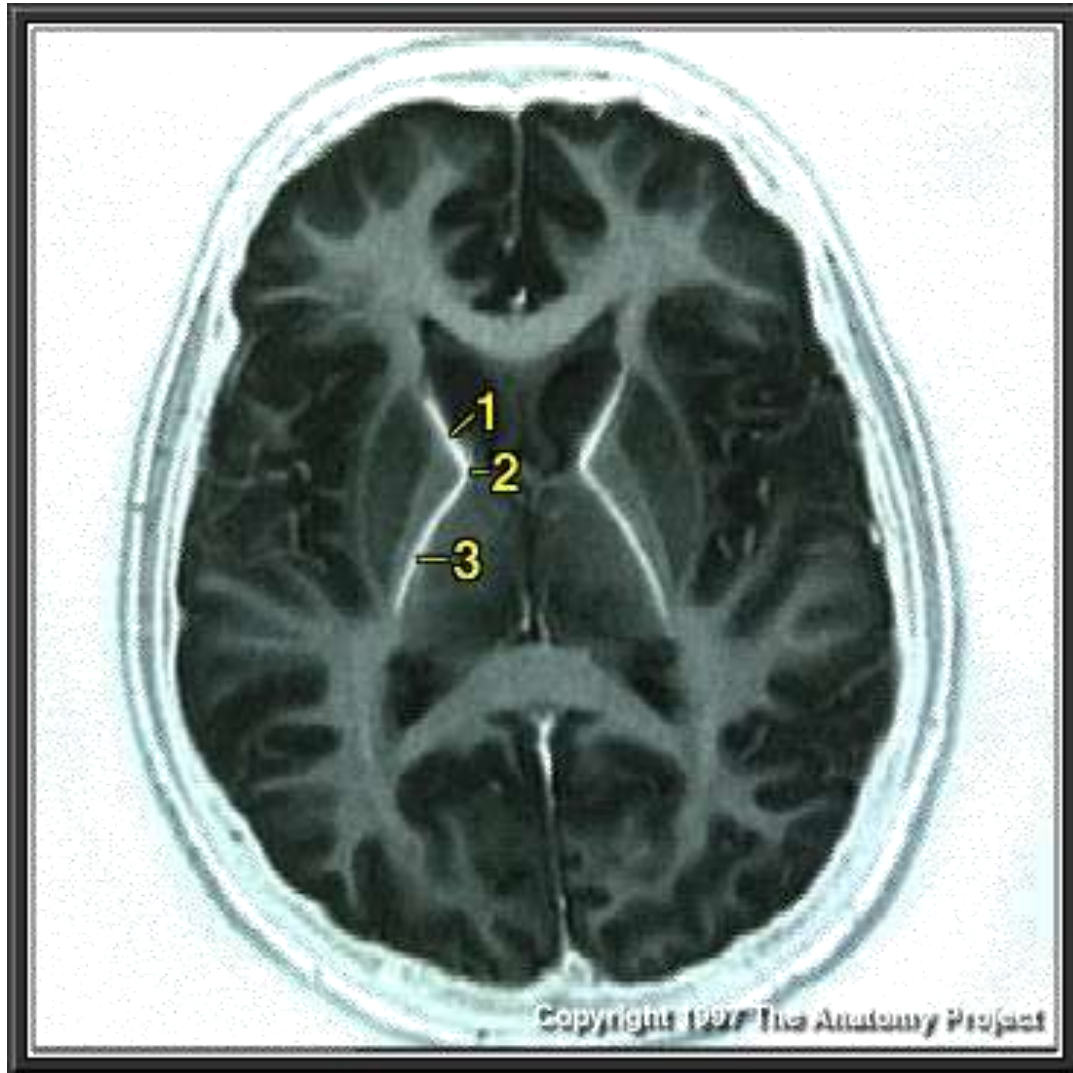
<http://www.emc.maricopa.edu/faculty/farabee/BIOBK/BioBookNERV.html>

Brain, sagittal sec, medial view



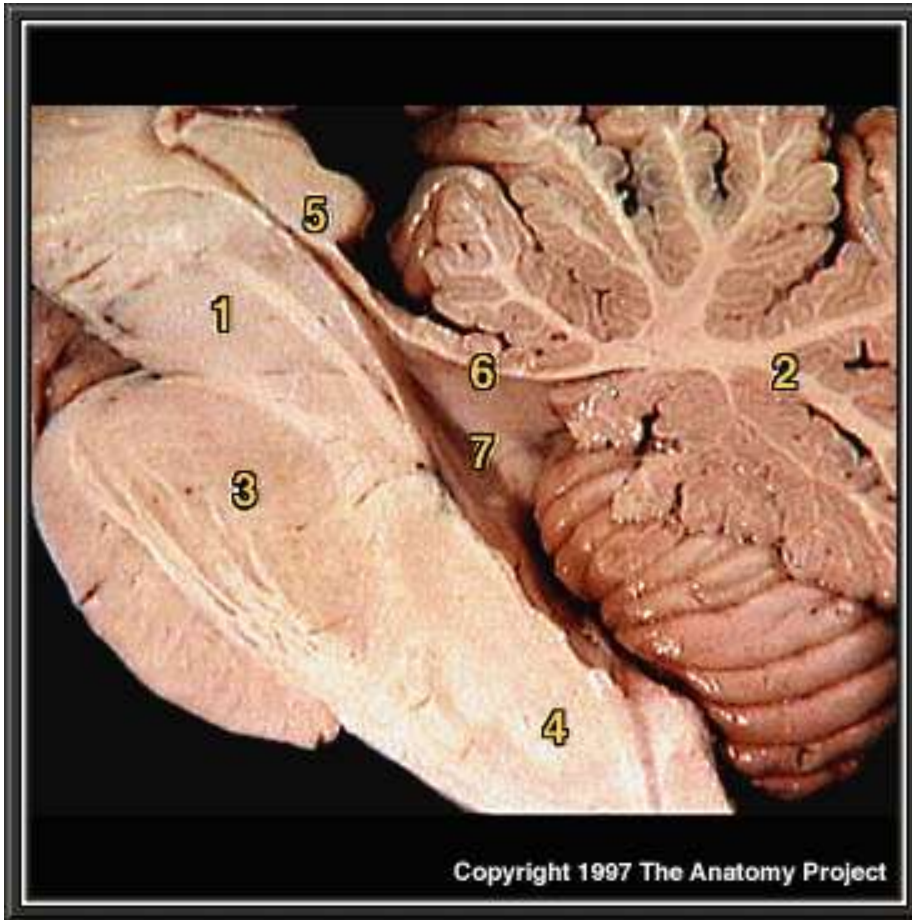
1. Cerebral hemisphere
2. Corpus callosum
3. Thalamus
4. Midbrain
5. Pons
6. Cerebellum
7. Medulla oblongata

Internal capsule



1. Anterior limb of internal capsule
2. Genu of internal capsule
3. Posterior limb of internal capsule

Pons & cerebellum, sagittal section, medial view



1. Midbrain
2. Cerebellum
3. Pons
4. Medulla oblongata
5. Inferior colliculus
6. Superior medullary velum
7. Fourth ventricle

You don't need to know #s 5 & 6)

Sagittal section through spinal cord

1. Intervertebral disc
2. Vertebral body
3. Dura mater
4. Extradural or epidural space
5. Spinal cord
6. Subdural space

